

Retinopatia Diabética não proliferativa

Biomarcadores no OCT

Ana Rita Santos

AIBILI

4º Simpósio de OCT - Hospital da Luz – 17 de Fevereiro de 2018

Retinopatia Diabética

Classificação Simplificada

- Sem retinopatia diabética
- Retinopatia diabética não proliferativa
- Retinopatia diabética proliferativa

Perda visual

- Edema macular diabético
- Retinopatia diabética proliferativa

Tomografia de Coerência Óptica - OCT

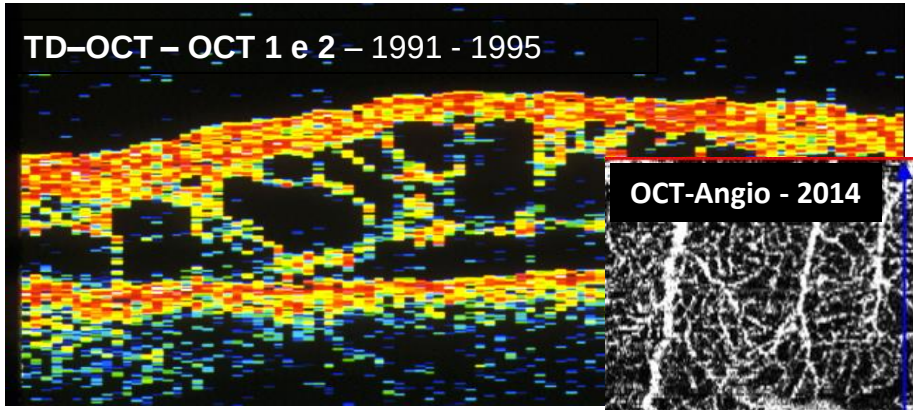

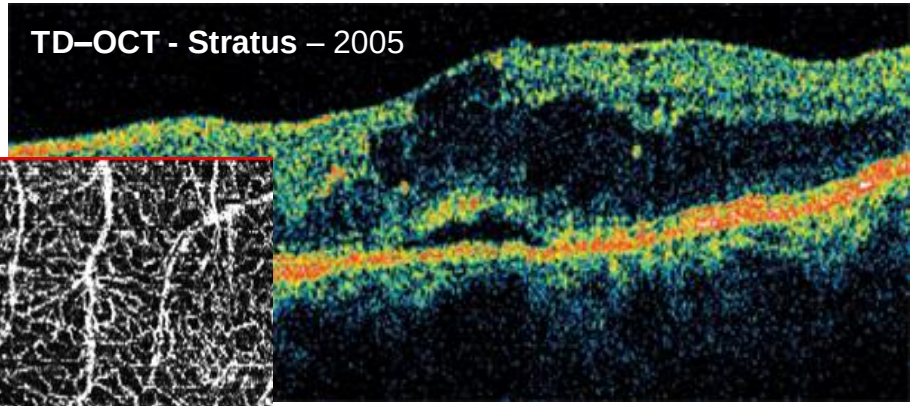

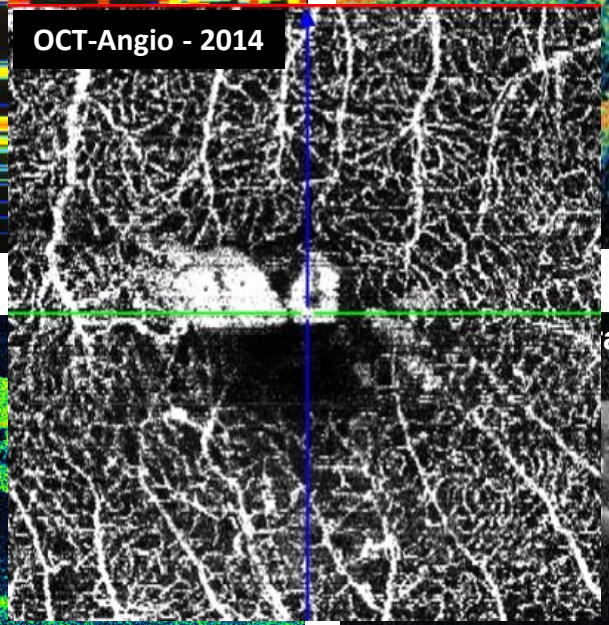

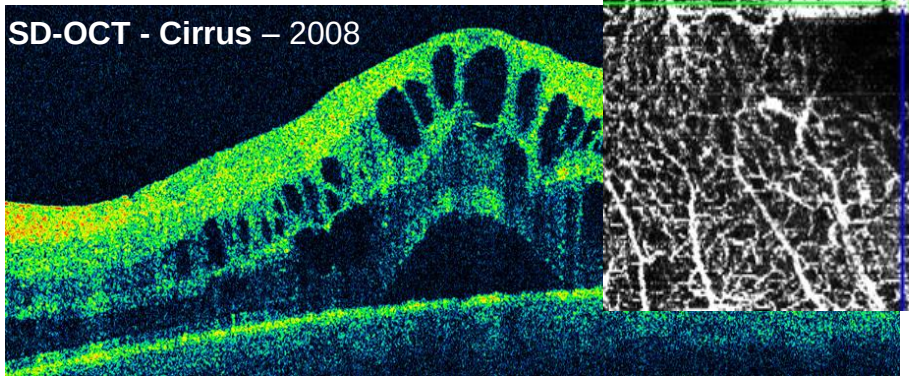

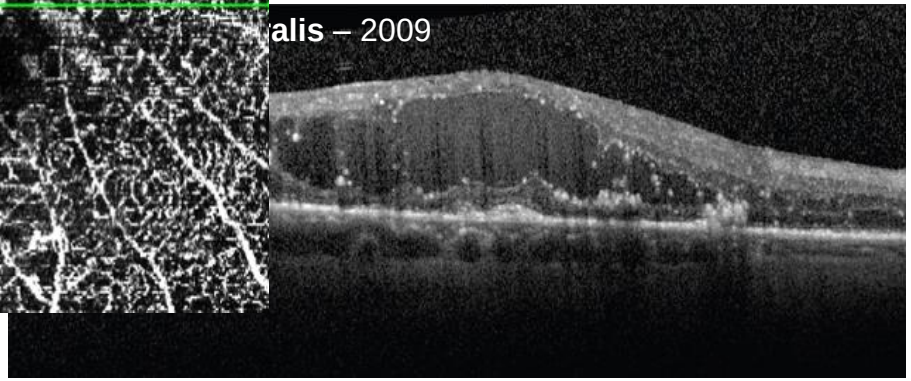

OCT

Fases Iniciais da Retinopatia Diabética

OCT - Sem Retinopatia Diabética

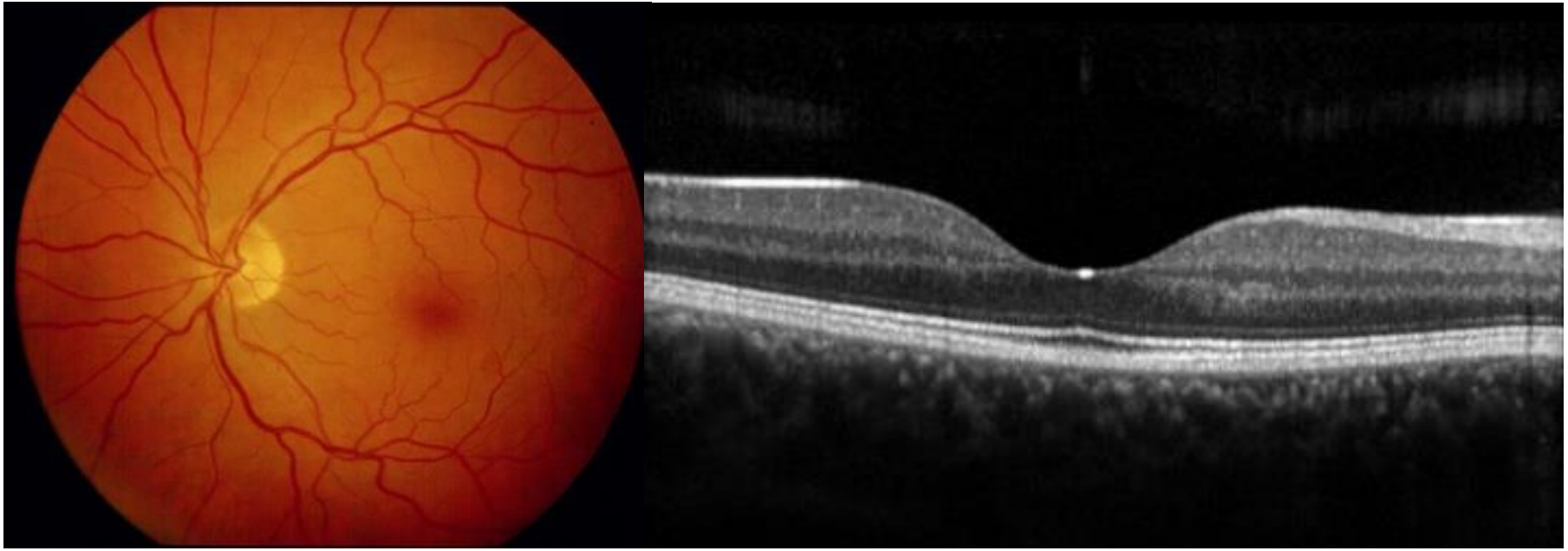

Retinografia e OCT normais

OCT - Retinopatia Diabética Não Proliferativa Ligeira

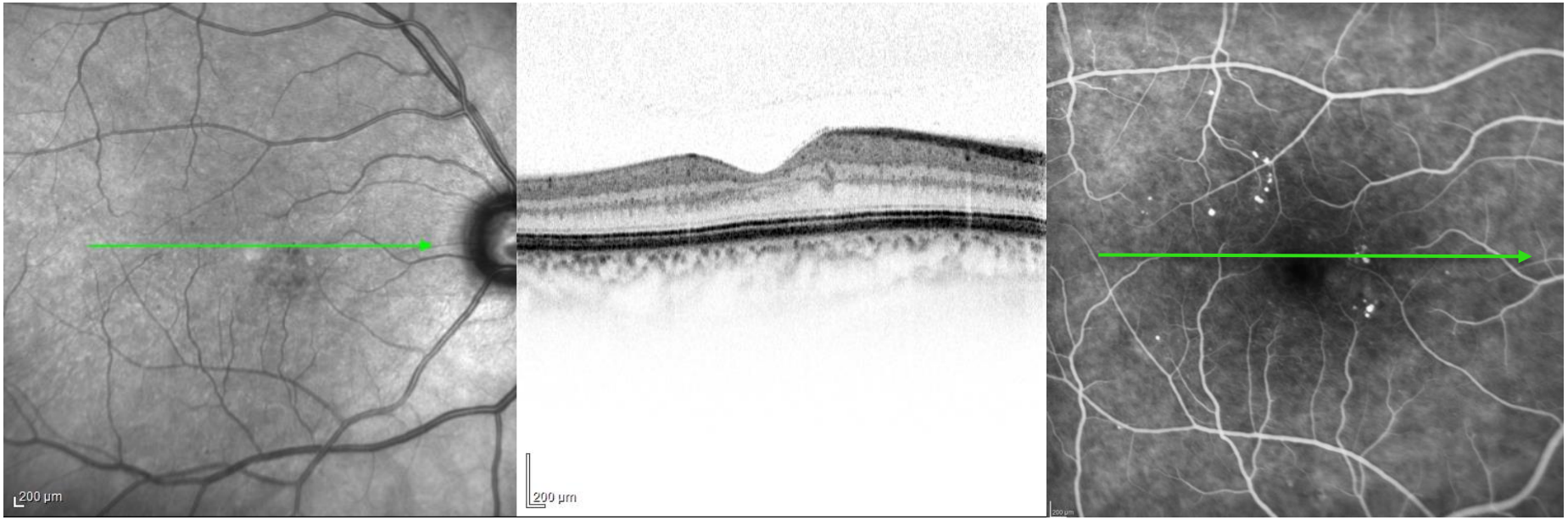

Utilidade limitada nas fases iniciais, apesar de aparentemente já existirem alterações precoces na espessura retiniana – **EM subclínico.**

Tejerina AN. et al, *Ophthalmic Res*. 2015. 54(3):118-23
Vujosevic S. et al, *Ophthalmic Res*. 2015. 55(1):19-25
DRCR.net et al, *Eye (Lond)*. 2012. 26(6):833-40

Edema Macular Diabético

Edema Macular Diabético

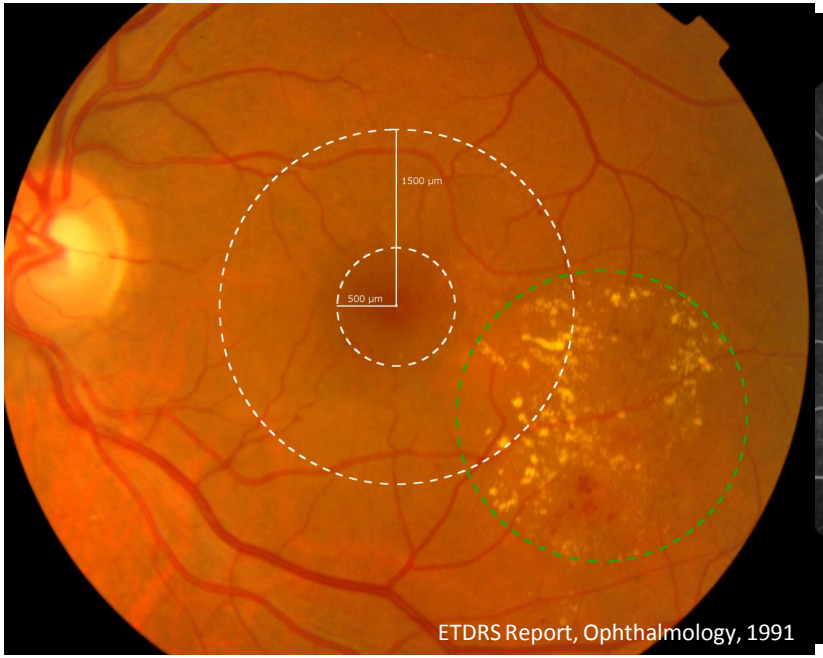

ETDRS Report, Ophthalmology, 1991

No passado, o diagnóstico de EMD:

Fundoscopia; Retinografias “Stereo”; Angiografia Fluoresceínica (métodos qualitativos)

OCT no Edema Macular Diabético

- **Diagnóstico**
- Quantificar e Localizar o EMD
- Avaliação estrutural da retina macular e interface vítreo-retiniana
- Monitorizar EMD: Avaliar a resposta terapêutica e decisão re-tratamento
- Biomarcador da resposta terapêutica

OCT no Edema Macular Diabético

OCT no Edema Macular Diabético

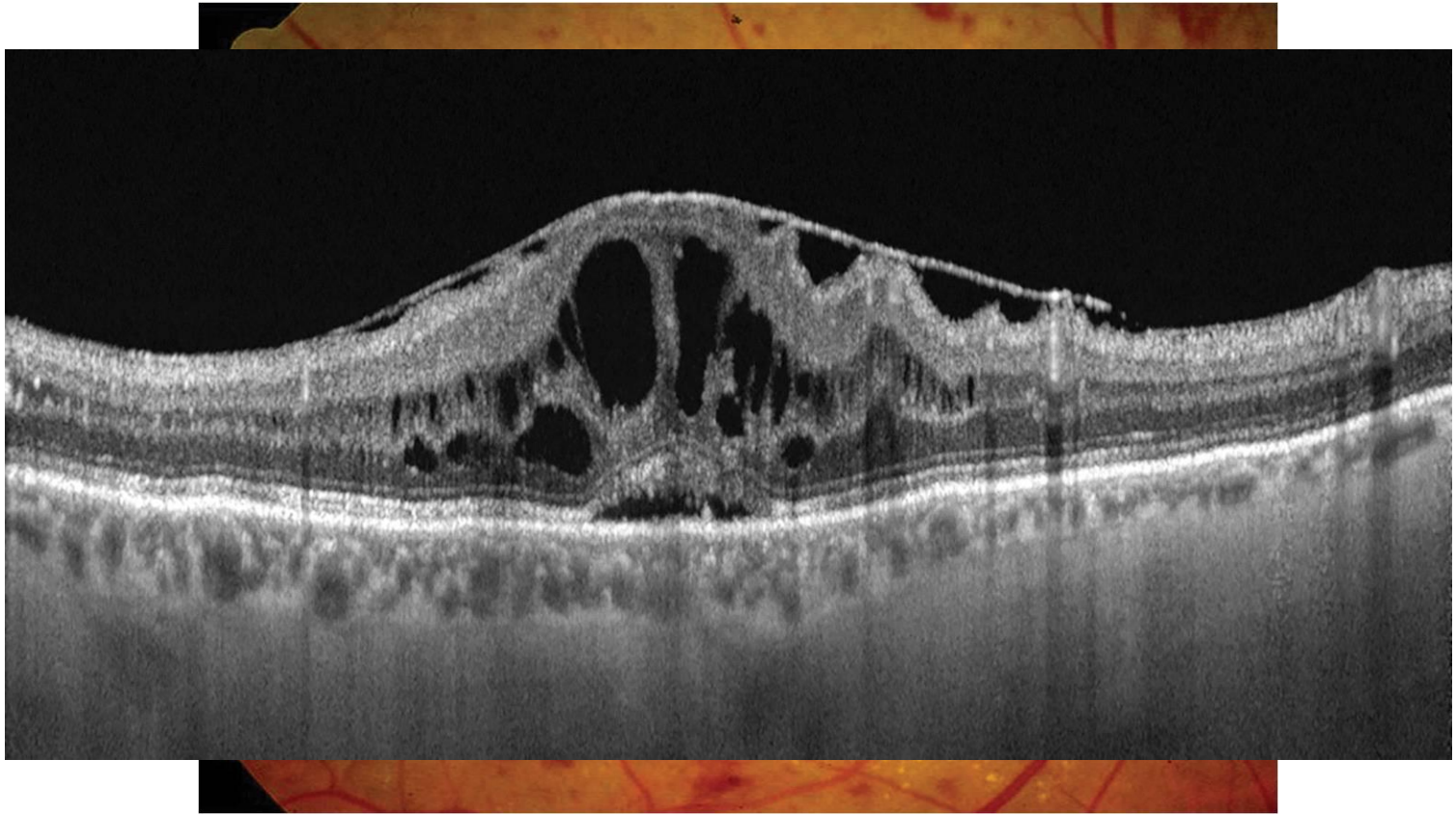

Edema Macular Diabético

Assintomático, AV: 20/20 ODE

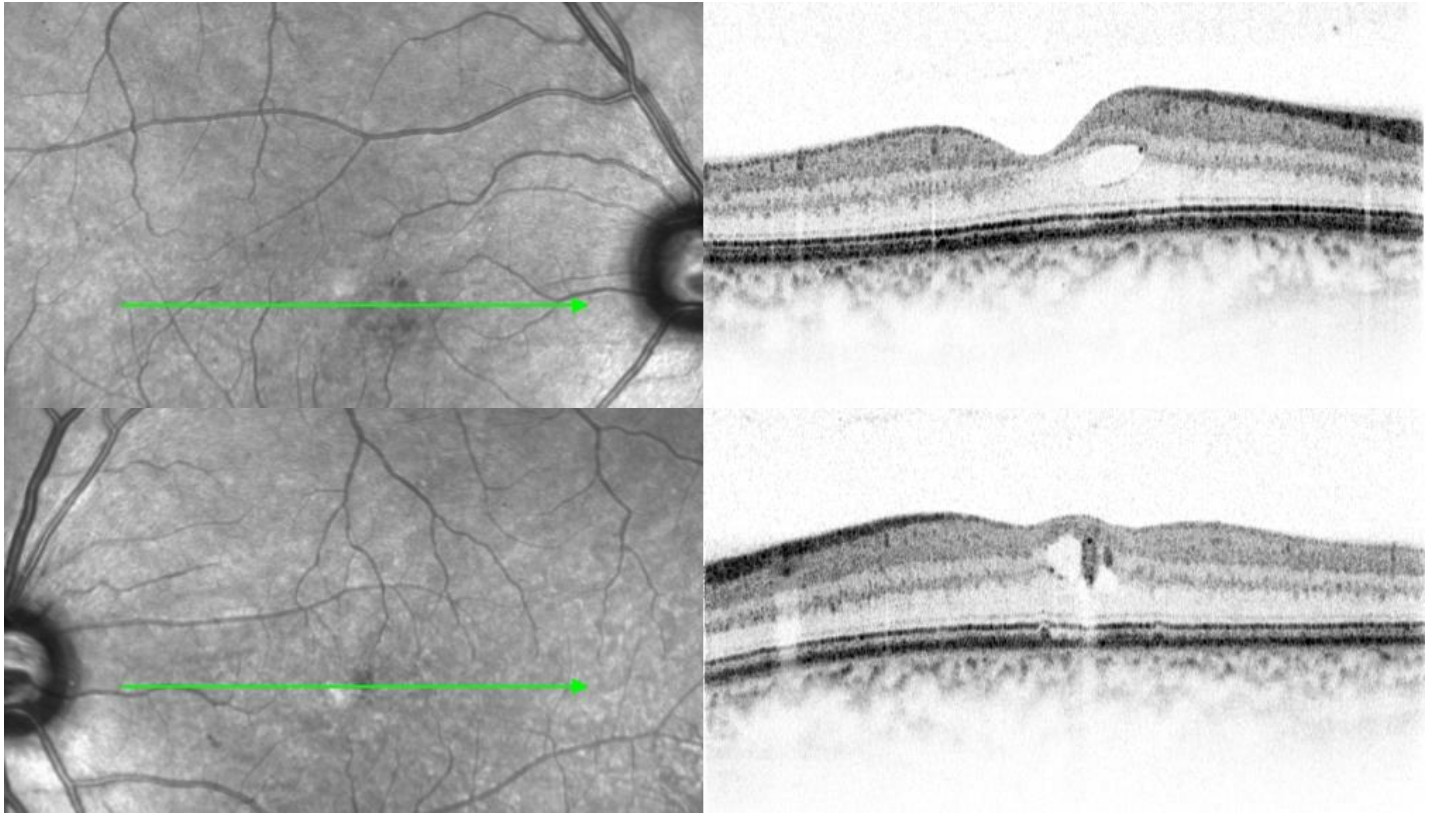

OCT no Edema Macular Diabético

- Diagnóstico
- **Quantificar e Localizar o EMD**
- Avaliação estrutural da retina macular e interface vítreo-retiniana
- Monitorizar EMD: Avaliar a resposta terapêutica e decisão re-tratamento
- Biomarcador da resposta terapêutica

Quantificação/Localização do Edema Macular Diabético

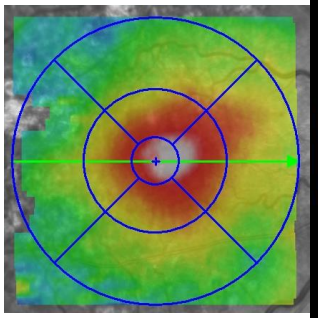

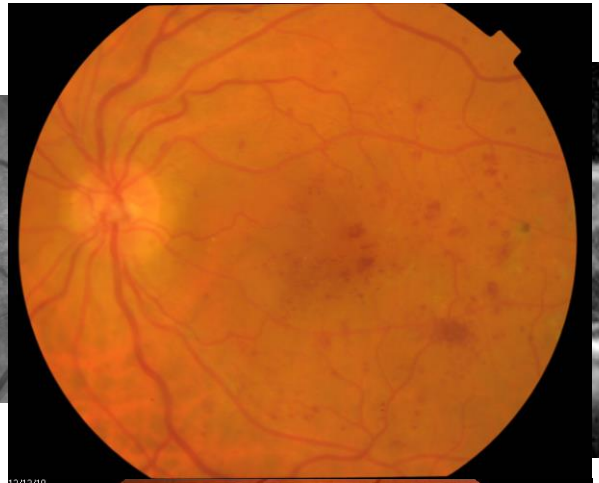

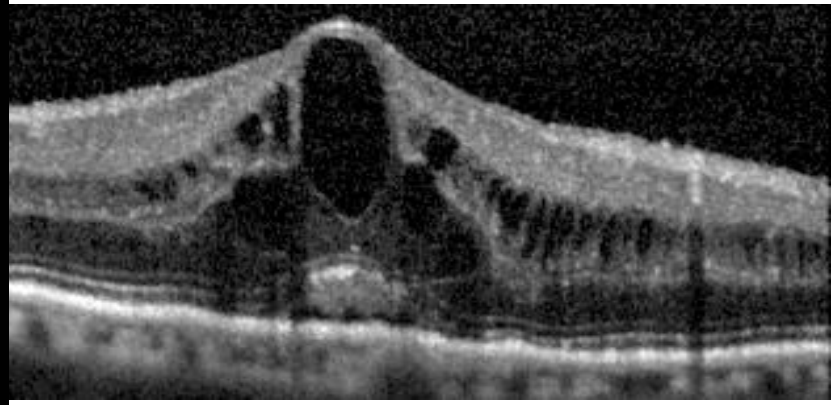

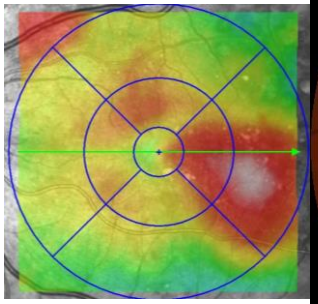



OCT no Edema Macular Diabético

- Diagnóstico
- Quantificar e Localizar o EMD
- **Avaliação estrutural da retina macular e interface vítreo-retiniana**
- Monitorizar EMD: Avaliar a resposta terapêutica e decisão re-tratamento
- Biomarcador da resposta terapêutica

Avaliação Estrutural da Retina Macular

Classificação do EMD em 3 tipos:

1. EMD Difuso
2. EMD Cistóide
3. EMD com descolamento neurossensorial foveal

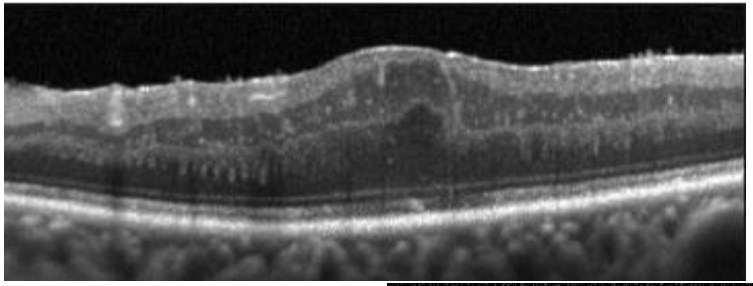

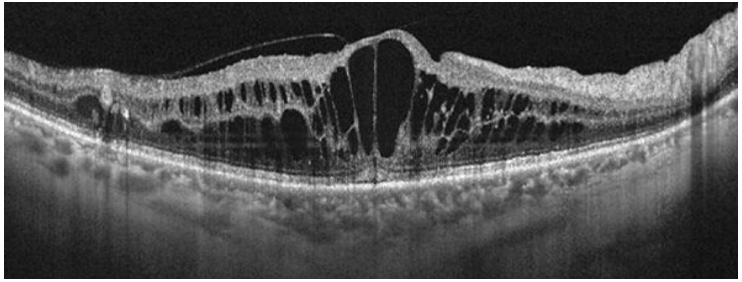

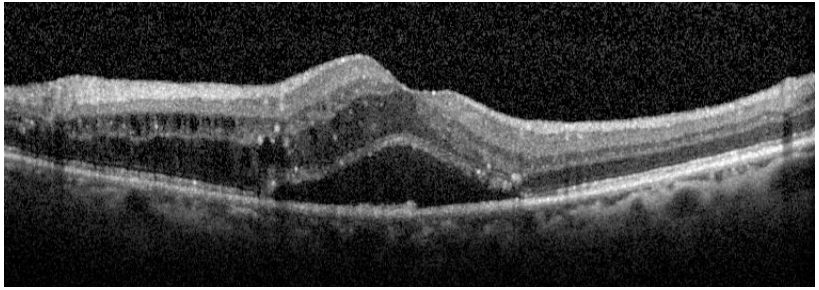

Otani T, et al. *Am J Ophthalmol*. 1999

Avaliação Estrutural da Retina Macular

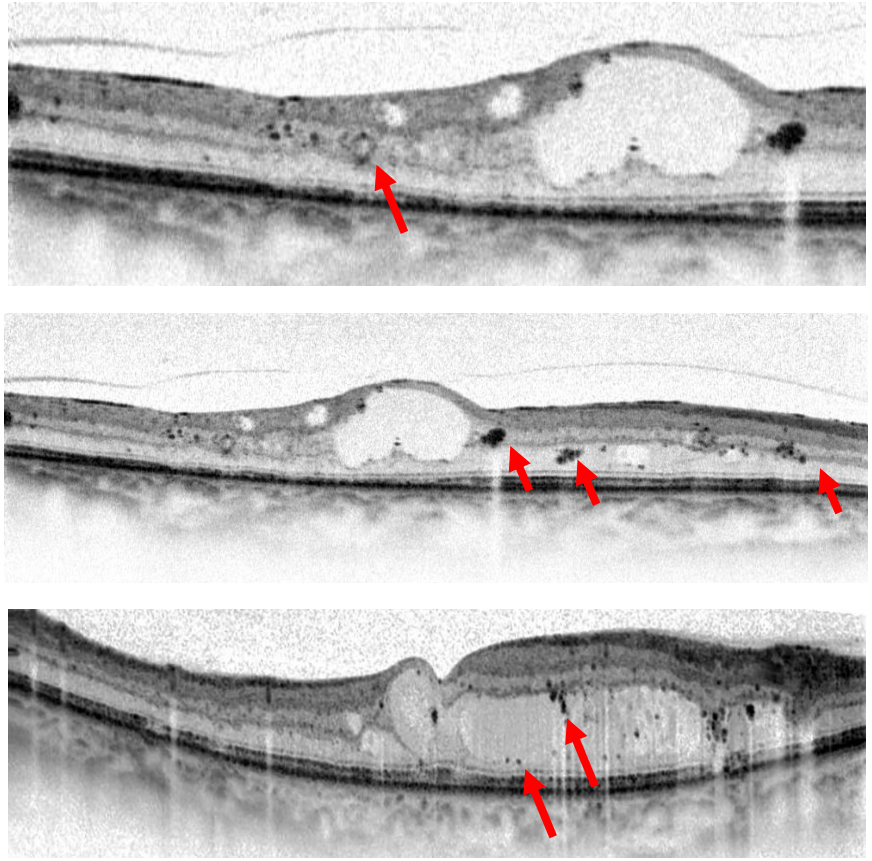

- **Microaneurismas:** A maioria encontram-se no plexo profundo ao nível da INL e EPL
- **Exsudados duros:** Pontos hiperreflectivos compostos por lipoproteinas - efeito sombra nas camadas mais externas da retina
- **Pontos hiperreflectivos:** pequenos e múltiplos focos hiperreflectivos, localizados na EPL e ao longo do contorno dos espaços cistóides, mas também na ELM. Não visíveis à fundoscopia - material exsudativo que evolui para exsudados duros

Hangai et al. *OCT Atlas*, 2012
Bolz et al, *Ophthalmology*, 2009

Interface vítreo-retiniana no EMD

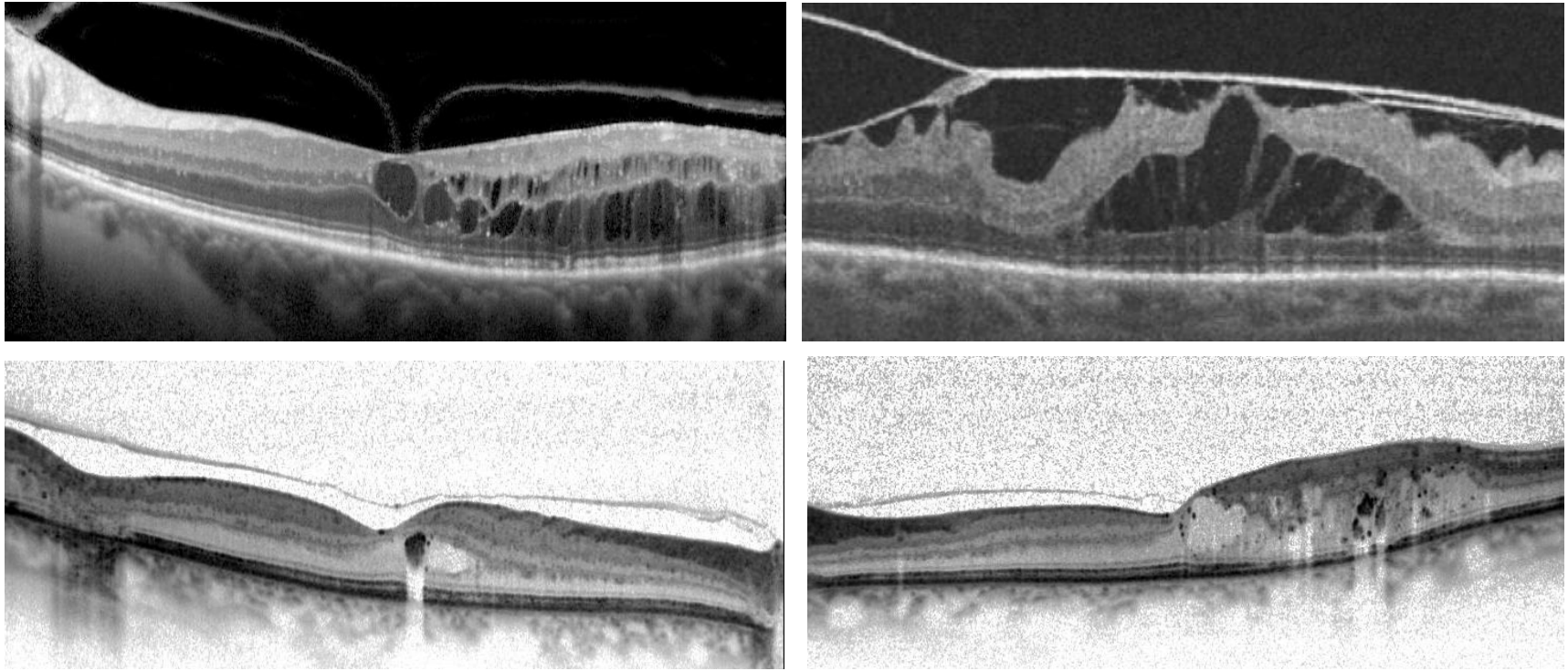

Kulikov AN, et al. *Clinical Ophthalmology* 2017

OCT no Edema Macular Diabético

- Diagnóstico
- Quantificar e Localizar o EMD
- Avaliação estrutural da retina macular e interface vítreo-retiniana
- **Monitorizar EMD: Avaliar a resposta terapêutica e decisão re-tratamento**
- Biomarcador da resposta terapêutica

Avaliar a resposta terapêutica / Re-tratamento

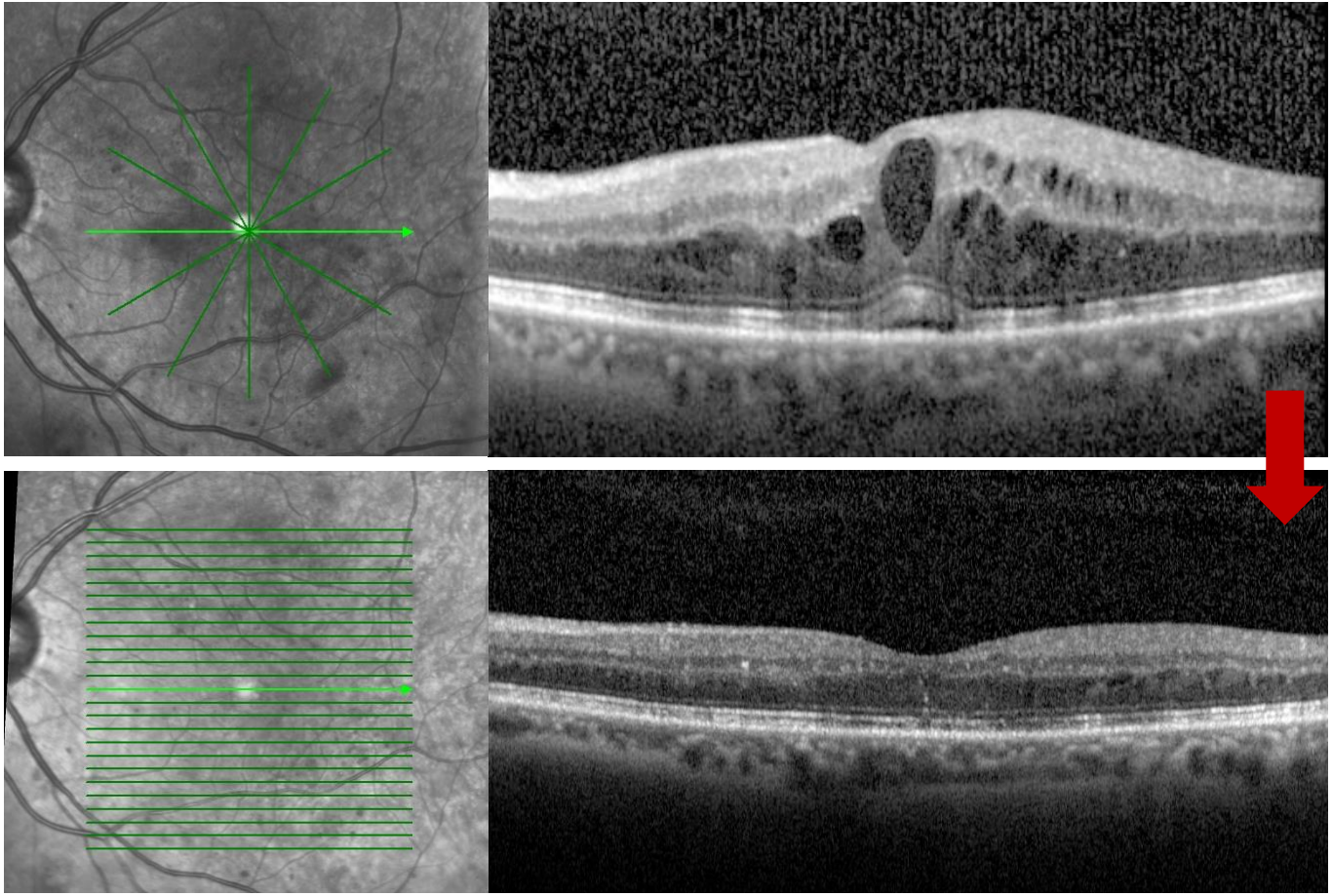

M, DM 2- 13 anos
67 anos
OE – 20/32

Antes

↓ RBZ

4 M Após

LE – 20/20

OCT no Edema Macular Diabético

- Diagnóstico
- Quantificar e Localizar o EMD
- Avaliação estrutural da retina macular
- Avaliar a Interface vítreo-retiniana
- Monitorizar EMD: Avaliar a resposta terapêutica e decisão re-tratamento
- **Biomarcador da resposta terapêutica**

RECUPERAÇÃO ESTRUTURAL = FUNCIONAL??





OCT - Biomarcador da resposta terapêutica

Localização dos quistos e camadas afectadas

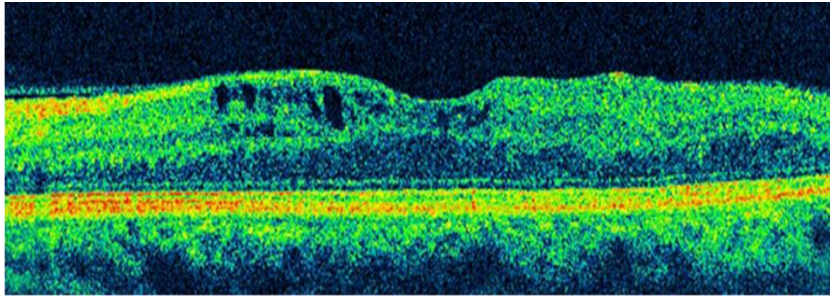

DME Type 2: Cysts in the inner layers

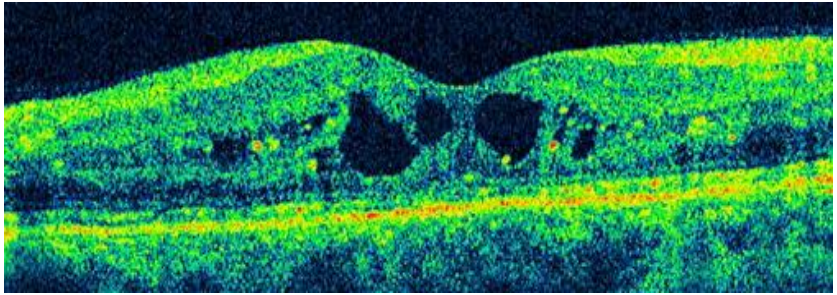

DME Type 3: Cysts in the outer layers

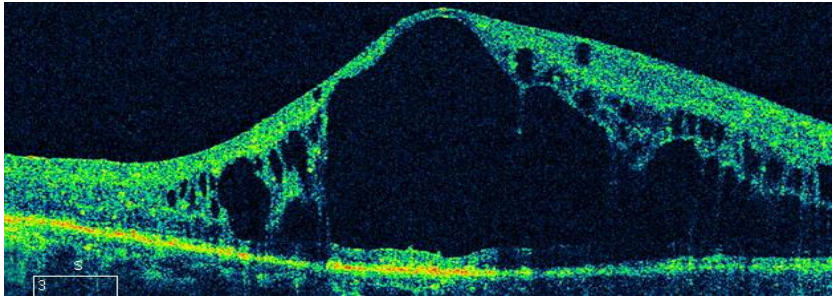

DME Type 4: Cystoid DME involving both inner and outer retina layers

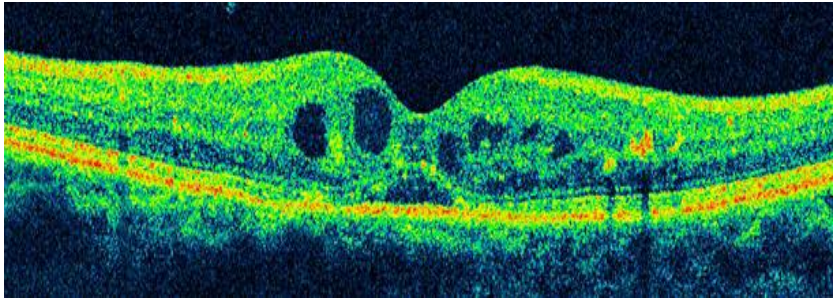

DME Type 5: Presence of serous retinal detachment

- Outer cystoid DME more frequent at baseline in the optimal responders group (93.9% *vs* 69%).
- Inner cystoid DME seems to be related with a poor response to the treatment (45% *vs* 70%).

Santos AR, et al. *Ophthalmologica.* 2013

OCT - Biomarcador da resposta terapêutica

Estudo CHARTRES - Prospective series of 71 DME naive patients treated with anti-VEGF

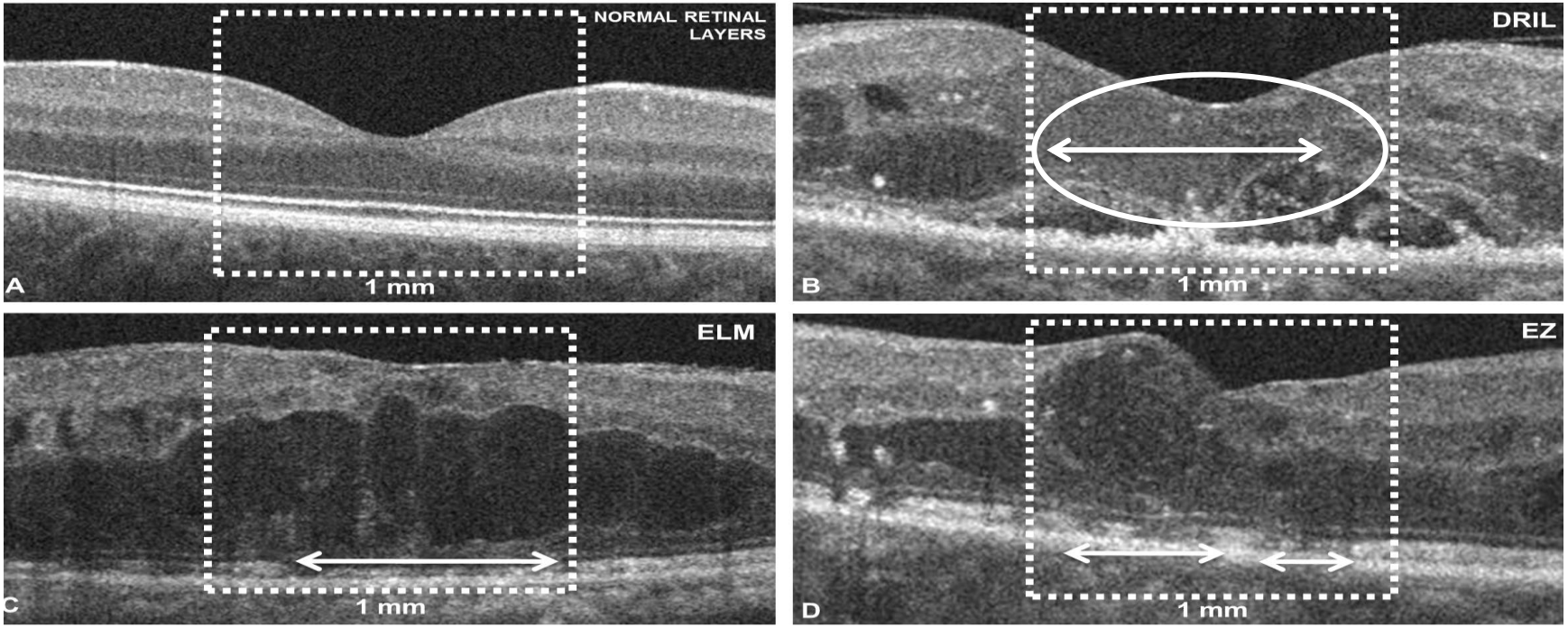

EZ: disruption of Ellipsoid Zone

DRIL: disruption of inner retinal layers

ELM: disruption external limiting membrane

Santos AR, et al. RETINA, 2017; ahead of print.

OCT - Biomarcador da resposta terapêutica

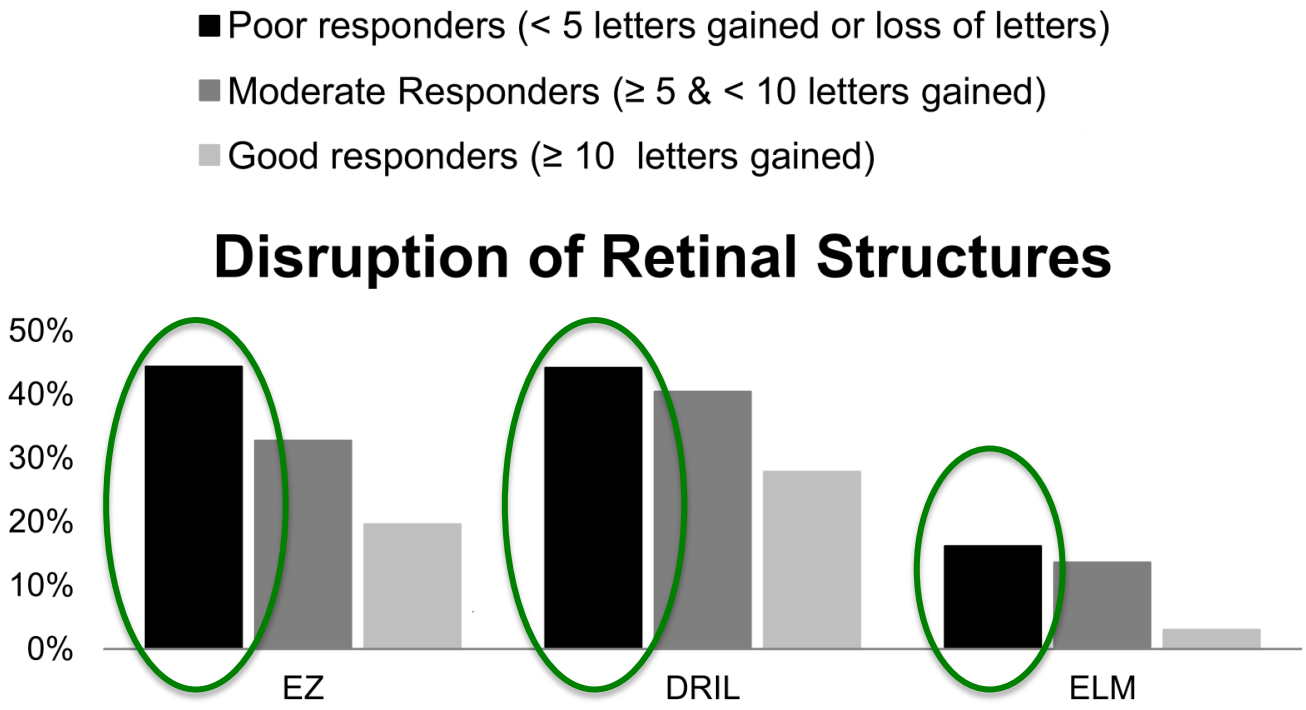

Alterações estruturais no SD-OCT estão associadas a uma pior resposta ao tratamento ($p<0.001$)

Santos AR, et al. RETINA, 2017; ahead of print.

OCT - Biomarcador da resposta terapêutica

Univariate and Multivariate Multinomial Logistic Regression Analysis of baseline OCT features with influence on BCVA treatment outcome

	Univariate Analysis				Multivariate Analysis			
	Moderate Responders		Poor Responders		Moderate Responders		Poor Responders	
Variables	OR (95%CI)	*P*	OR (95% CI)	*P*	OR (95%CI)	*P*	OR (95% CI)	*P*
BCVA	1.03 (0.96-1.11)	0.421	0.97 (0.92-1.03)	0.399	1.09 (0.99-1.20)	0.076	1.03 (0.93-1.13)	0.589
CRT	1.00 (1.00-1.01)	0.230	1.00 (0.99-1.00)	0.526	1.00 (1.00-1.01)	0.512	0.98 (0.97-1.00)	**0.001**
DRIL area	1.03 (0.20-5.26)	0.970	**4.58 (1.18-17.79)**	**0.028**	0.88 (0.15-5.03)	0.886	**7.05 (1.16-42.89)**	**0.034**
EZ disruption area	1.93 (0.84-4.40)	0.120	**3.93 (1.72-8.94)**	**0.001**	2.72 (0.86-8.64)	0.090	**10.96 (2.94-40.8)**	**<0.001**
Cystoid Spaces Severity	1.50 (0.65-3.48)	0.336	1.32 (0.59-2.94)	0.501	-	-	-	-
NSD	1.94 (0.53-7.17)	0.318	2.31 (0.66-8.03)	0.189	-	-	-	-
Epiretinal Membrane	0.60 (0.15-2.39)	0.469	1.88 (0.57-6.12)	0.297	-	-	-	-

(-): Variables not included in the multivariate analysis.
OR = Odds Ratio; CI = Confidence Interval; *P* = p-value; BCVA = Best Corrected Visual Acuity; CRT = Central Retinal Thickness; DRIL = Disorganization of Retinal Inner Layers; EZ = Ellipsoid Zone; NSD = Neurosensorial Serous Detachment

EZ damage offers a better predictive value for VA recovery than DRIL

Santos AR, et al. RETINA, 2017; ahead of print.

OCT - Biomarcador da resposta terapêutica

EMD representa, maioritariamente, acumulação de fluido na retina.

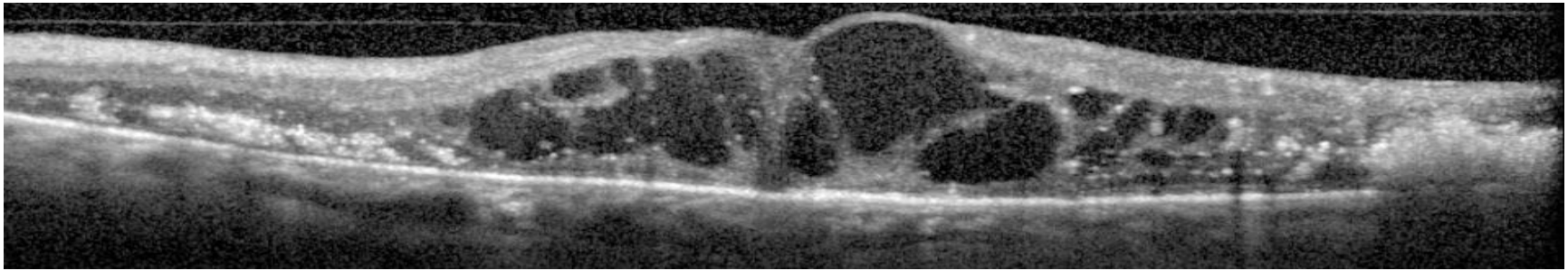

- OCT não quantifica a acumulação de fluido.
- Necessidade de um **novo método** (baseado em OCT) para **identificar e quantificar** fluido retiniano.

OCT-Leakage

Cunha-Vaz J, et al. IOVS. 2016 Dec 1;57(15):6776-6783

OCT LEAKAGE: Algorithm to identify Retinal Extracellular fluid changes

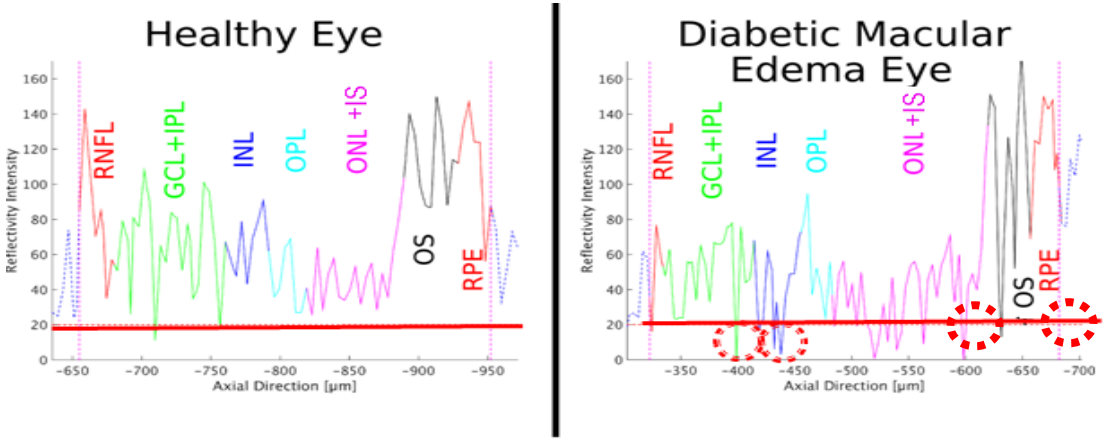



A) RNFL
B) GCL+IPL
C) INL
D) OPL
E) ONL+IS
F) OS (EZ)
G) RPE

Nos pacientes com EMD:

Locais com reflectividade abaixo do limiar normal

(LOR sites)

Lower Optical Reflectivity Sites

OCT LEAKAGE: Measurements of lower than normal optical reflectivity

$$\textbf{LOR Area Ratio} = \frac{\text{number of A scans below the “normal” threshold}}{\text{total of number of A scans in the same area}}$$

Maps of LOR Sites: full retina scan and layer by layer

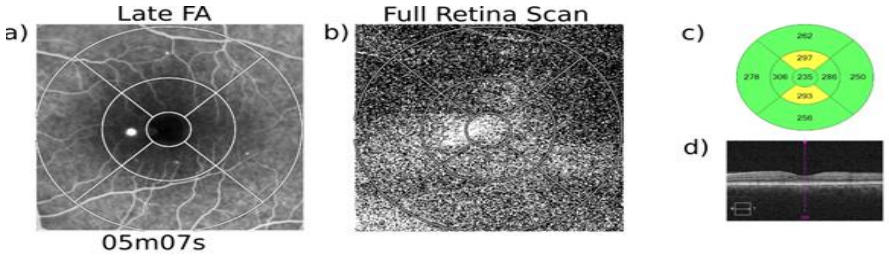



Cunha-Vaz et al. Invest. Ophthalmol. Vis Sci. 2016; 57:6776–83

Estudo prospectivo em 21 olhos com EMD *(treatment naïve)*:

- **Comparar biomarcadores estruturais (CRT, DRIL, EZ) com OCT-Leakage.**
- *Baseline* vs 1 semana após a 1a injecção anti-VEGF

- Resposta: BCVA 1 mês após a injecção:
    - Good responders 8 (38%)
    - Responders 5 (24%)
    - Poor responders 8 (38%)

Santos AR et al. Retina 2017 Oct 26

LOR RATIOS and BCVA after 1 month of anti-VEGF treatment

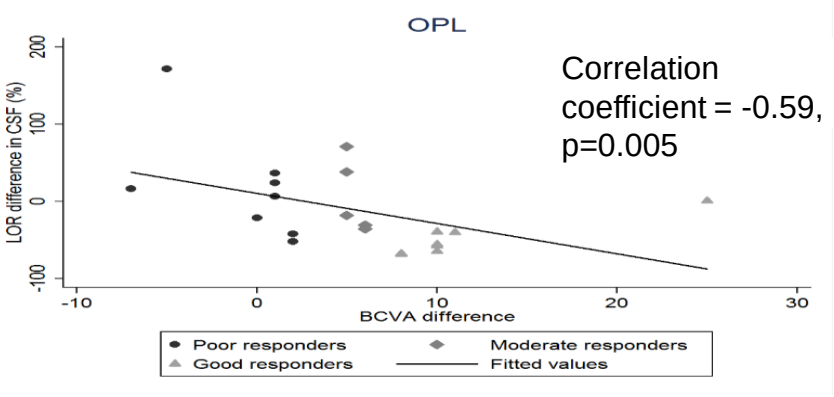

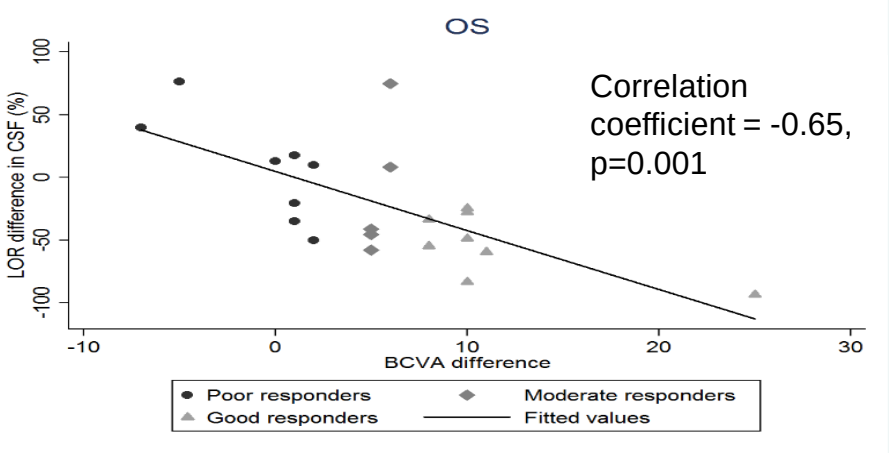

Boa correlação entre **OCT-Leakage** (LOR ratios) e a **BCVA** após o tratamento, independentemente da BCVA na *baseline*

Santos AR et al. Retina 2017. Oct 26

OCT LEAKAGE: melhor discriminador da resposta funcional ao tratamento (BCVA), que a CRT, EZ e DRIL

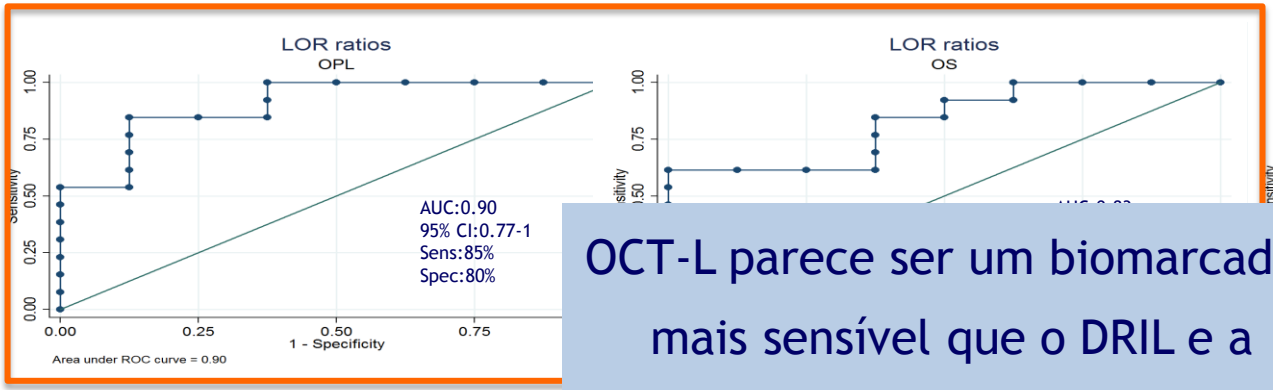

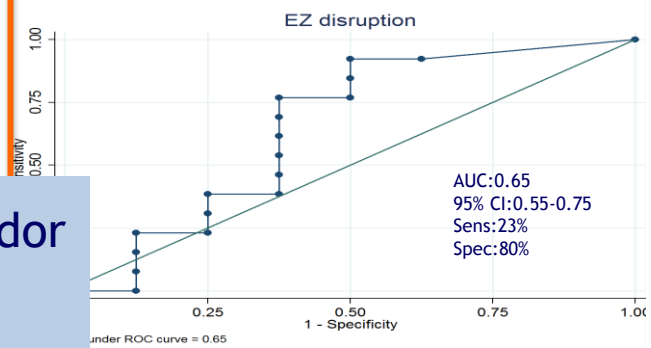

OCT-L parece ser um biomarcador mais sensível que o DRIL e a disrupção da EZ, para a recuperação visual após tratamento com anti-VEGF.

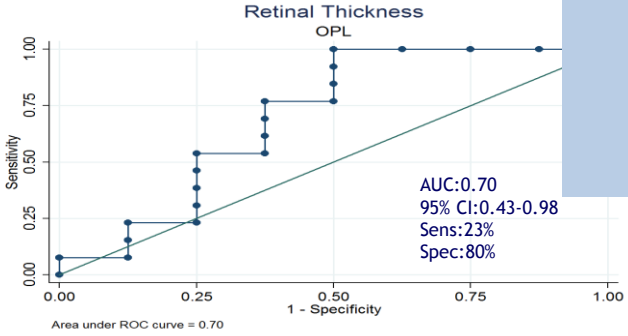



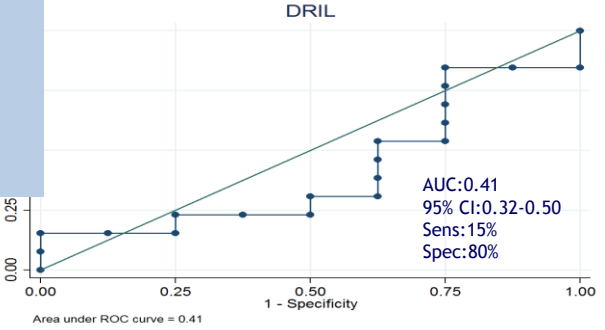

Santos AR et al. Retina 2017. Oct 26

OCT-LEAKAGE: BIOMARCADOR DA RESPOSTA TERAPÊUTICA

Before treatment

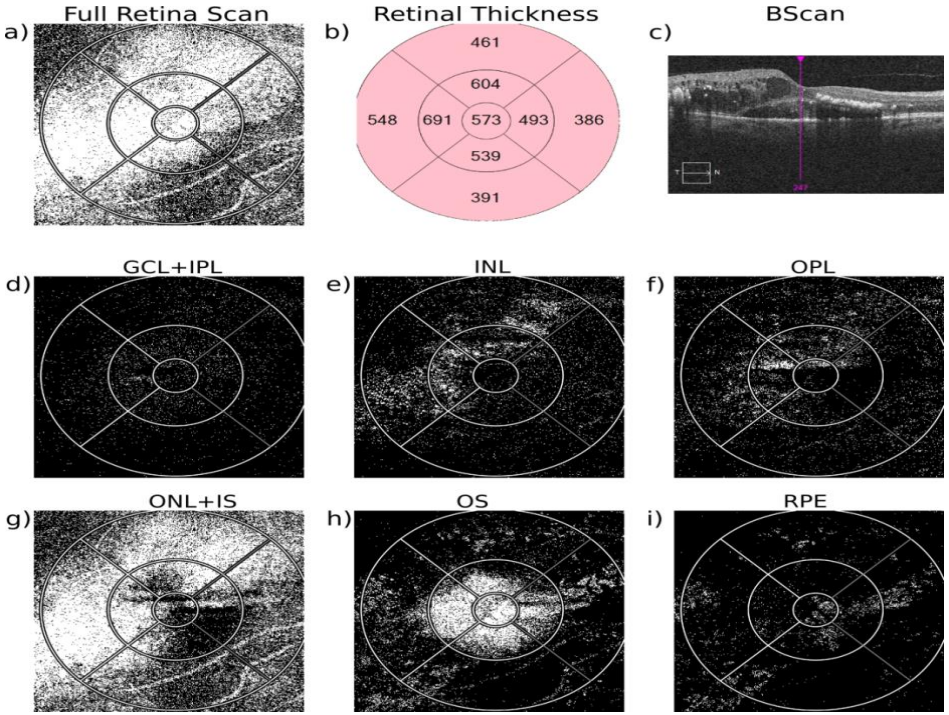

After treatment (1st injection)

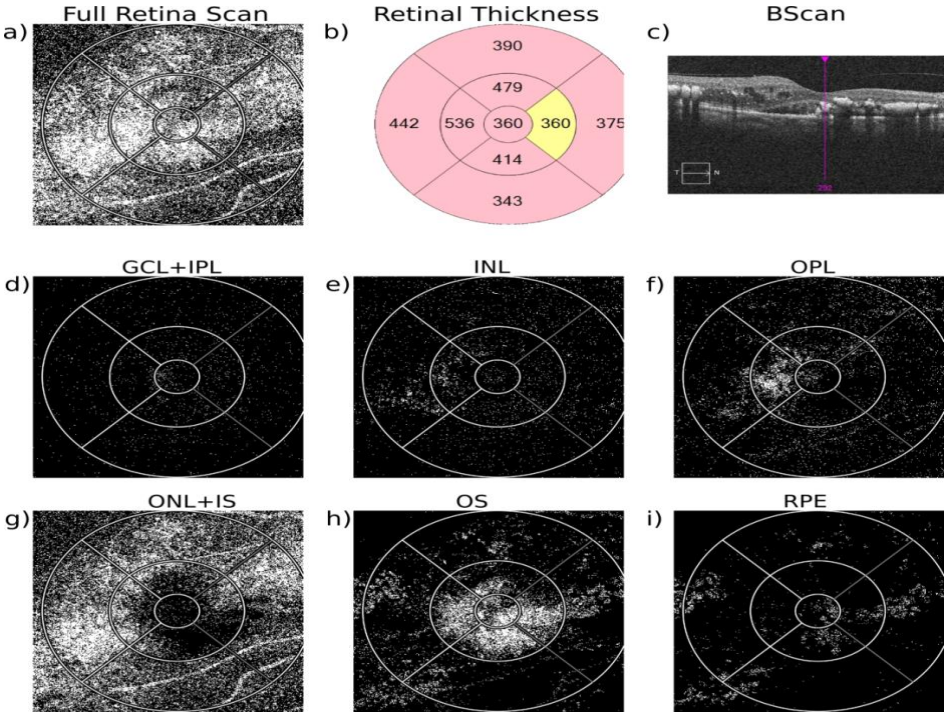

OCT - ANGIOGRAFIA

RDNP INICIAL - ALARGAMENTO DA FAZ (ZONA AVASCULAR FOVEAL)

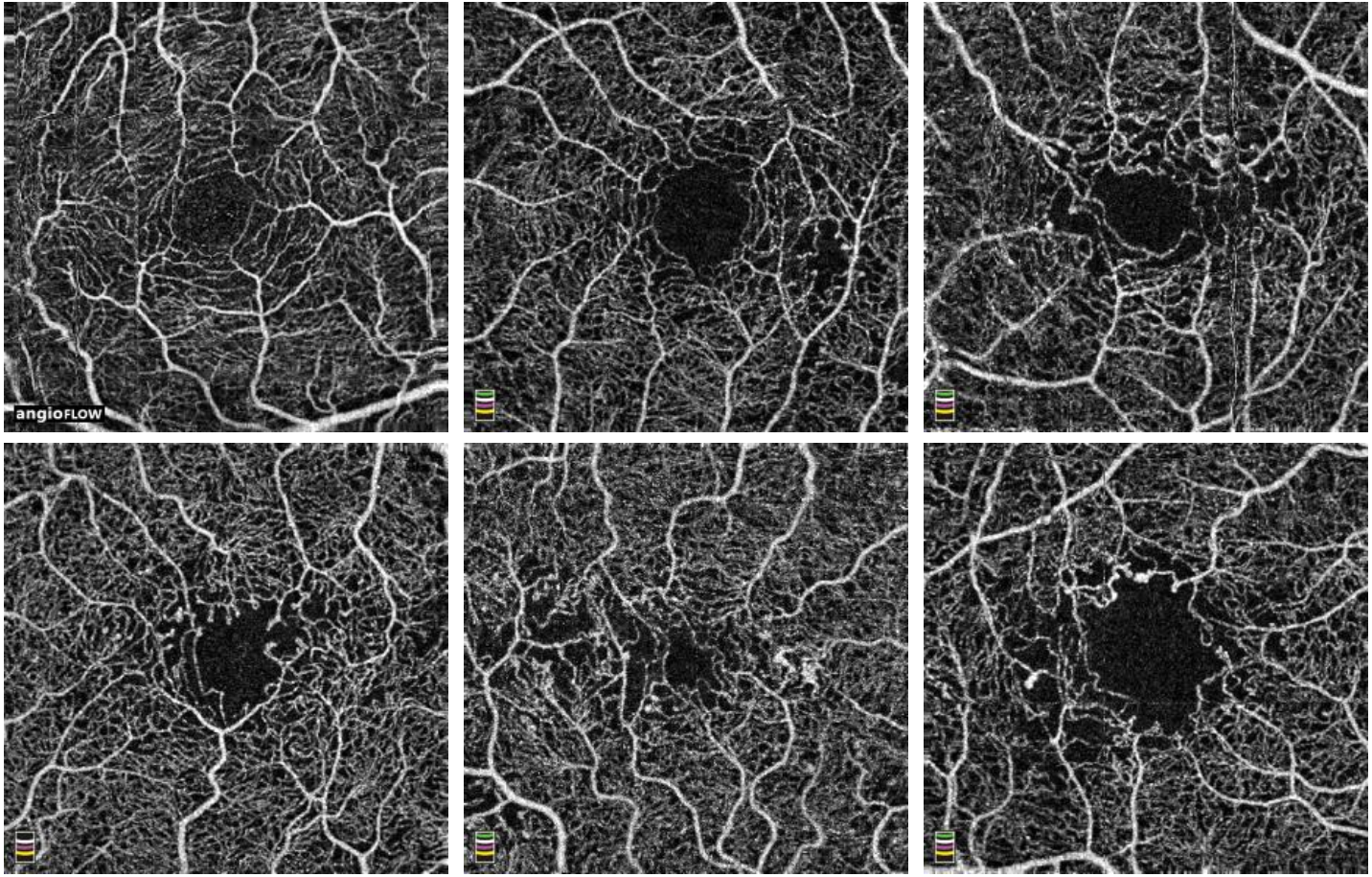

RDNP Inicial – Diminuição da densidade vascular



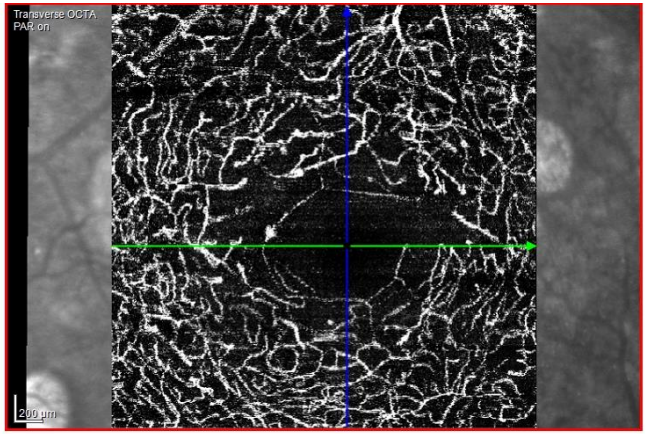

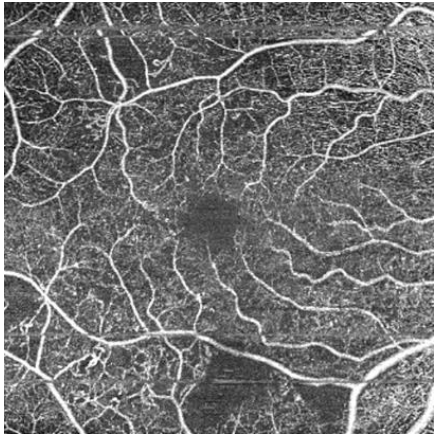

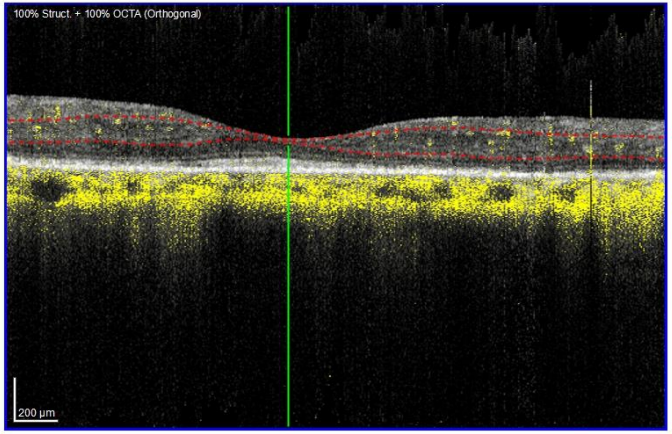

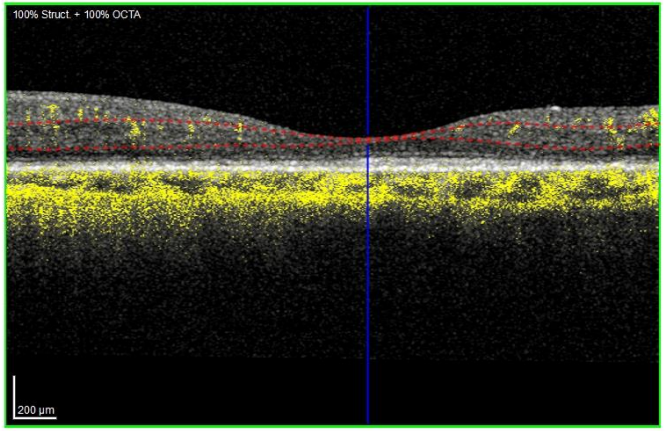

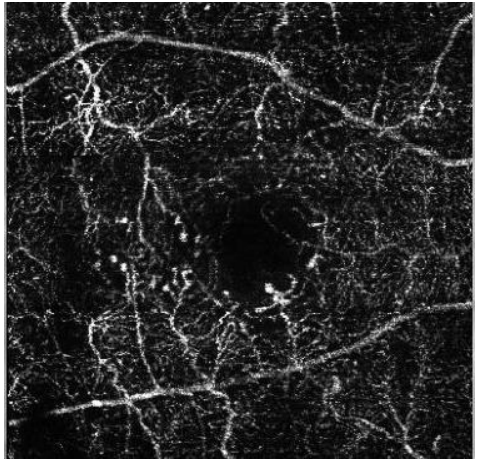

30-01-2018, OS, Transverse Structural OCT [Mean from IPL [-] to OPL], Transverse OCTA [Contrast 1:4, from IPL [-] to OPL; PAR on]

HEIDELBERG ENGINEERING

RDNP - Métricas de OCT-A – Biomarcadores?

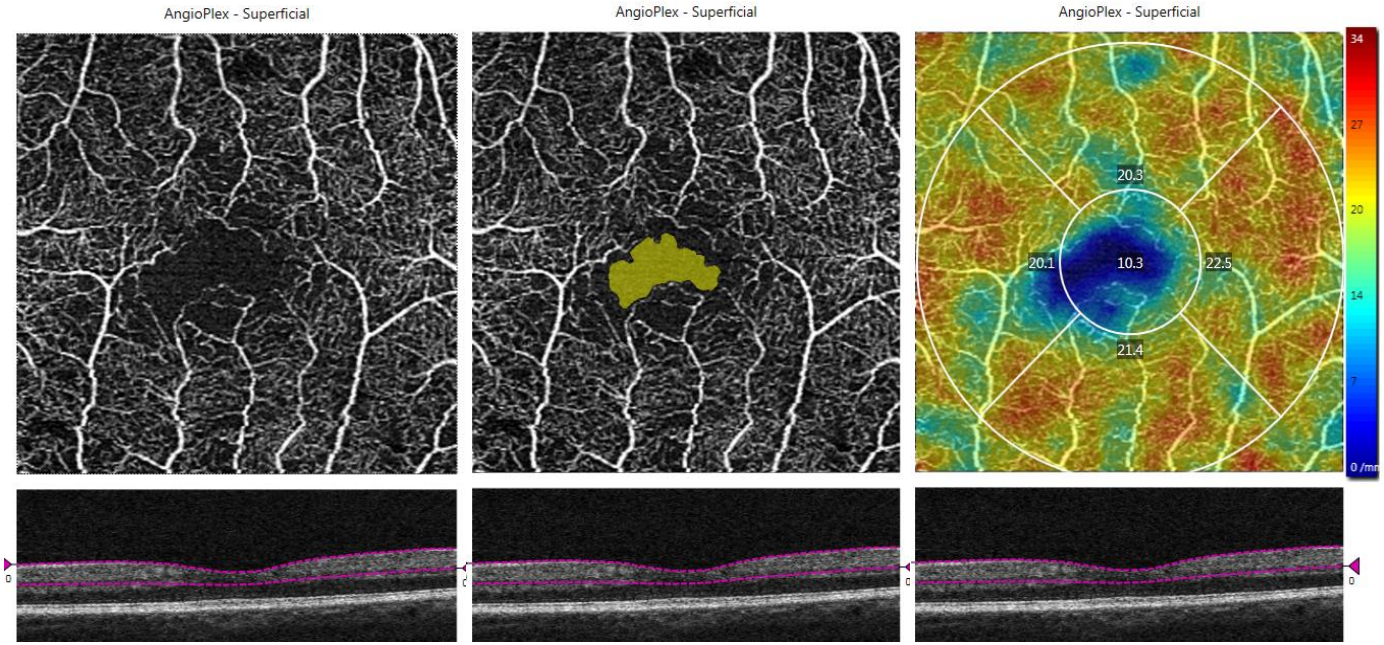

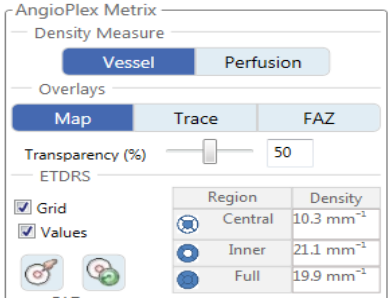

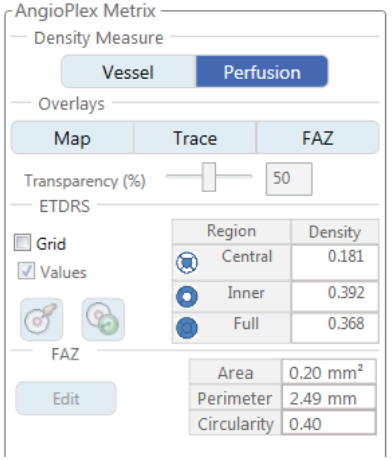

Densidade Vascular do Plexo Superficial:

- melhor diferenciador entre olhos “normais” e olhos com RD
- correlação significativa com BCVA, CRT e severidade da RD

Zona Avascular Foveal (FAZ):

- grande variabilidade, mesmo em indivíduos saudáveis

Durbin M, Cunha-Vaz J, et al. JAMA Ophthalmol. 2017;135(4):370-376.

OBRIGADA

Ana Rita Santos

asantos@aibili.pt