Technique and indications of extended retinacular flap & relative neck lengthening

L. Turchetto

Acknowledgement with Thanks to Prof. R.Ganz

Portogruaro 2005

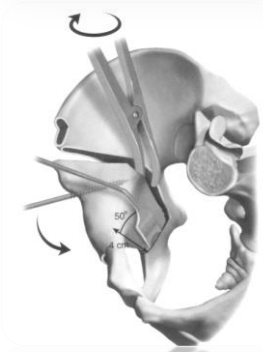

1988

2000

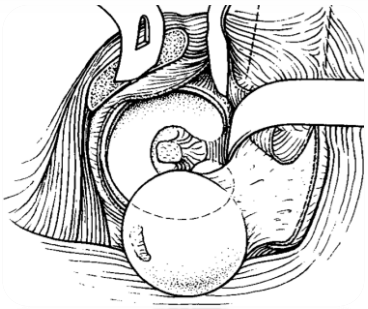

2001

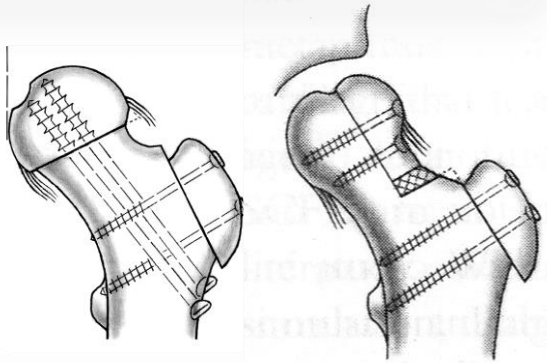

2009

2009 Extended retinacular soft-tissue flap

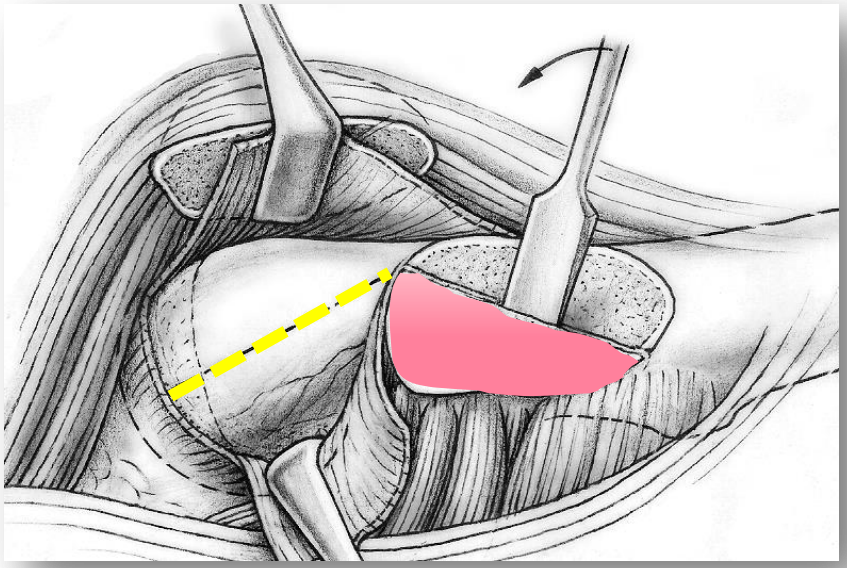

- after trochanteric osteotomy the posterior portion of the trochanter is reduced subperiosteally
- incision of the neck periosteum anterior to the retinacular fold
- retinacular flap is developed strictly subperiosteally around the entire neck

R. Ganz, Instr Course Lecture 2009; 48: 241-255

Extended retinacular soft-tissue flap

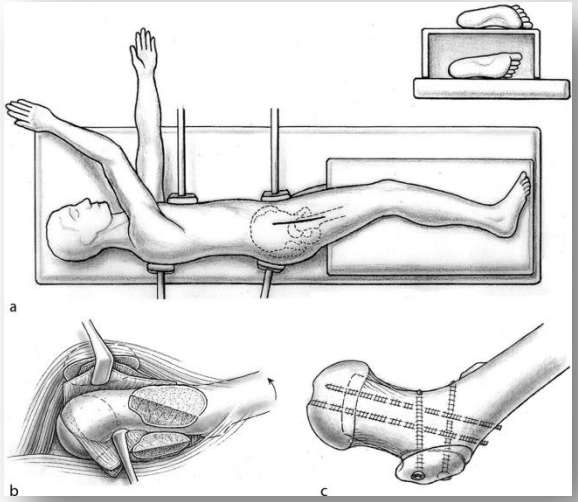

Workhorse for :

- relative lengthening of femoral neck
- subcapital reorientation
- true femoral neck osteotomy
- femoral head osteotomy

Relative femoral neck lengthening

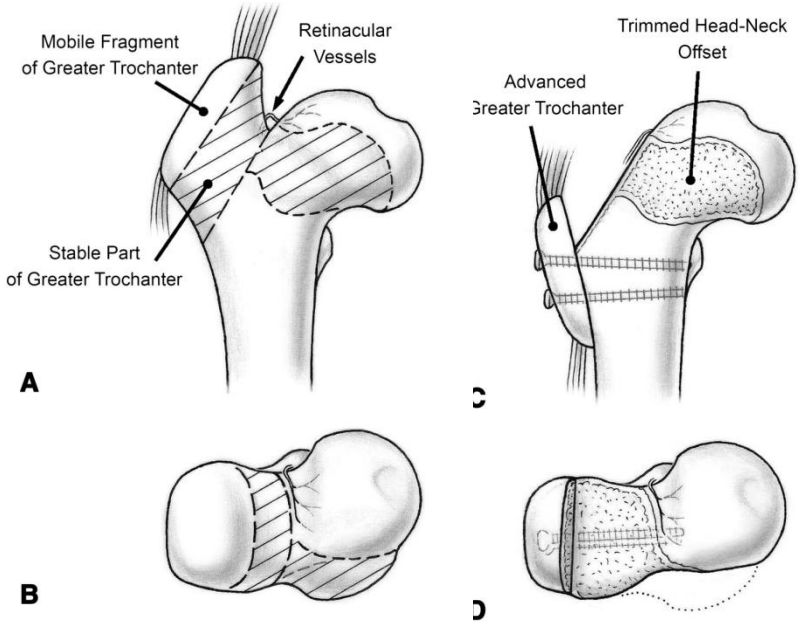

- high-riding trochanter
- short neck
- decreased offset.

- reduction of the stable part of the greater trochanter
- osteochondroplasty of the femoral headneck area to improve offset
- advancement of the mobile trochanteric fragment.

Ganz R. , AAOS Instr Course 2009
Tannast M, Macintyre N, Steppacher SD, Hosalkar HS, Ganz R, Siebenrock KA. Hip Int. 2013

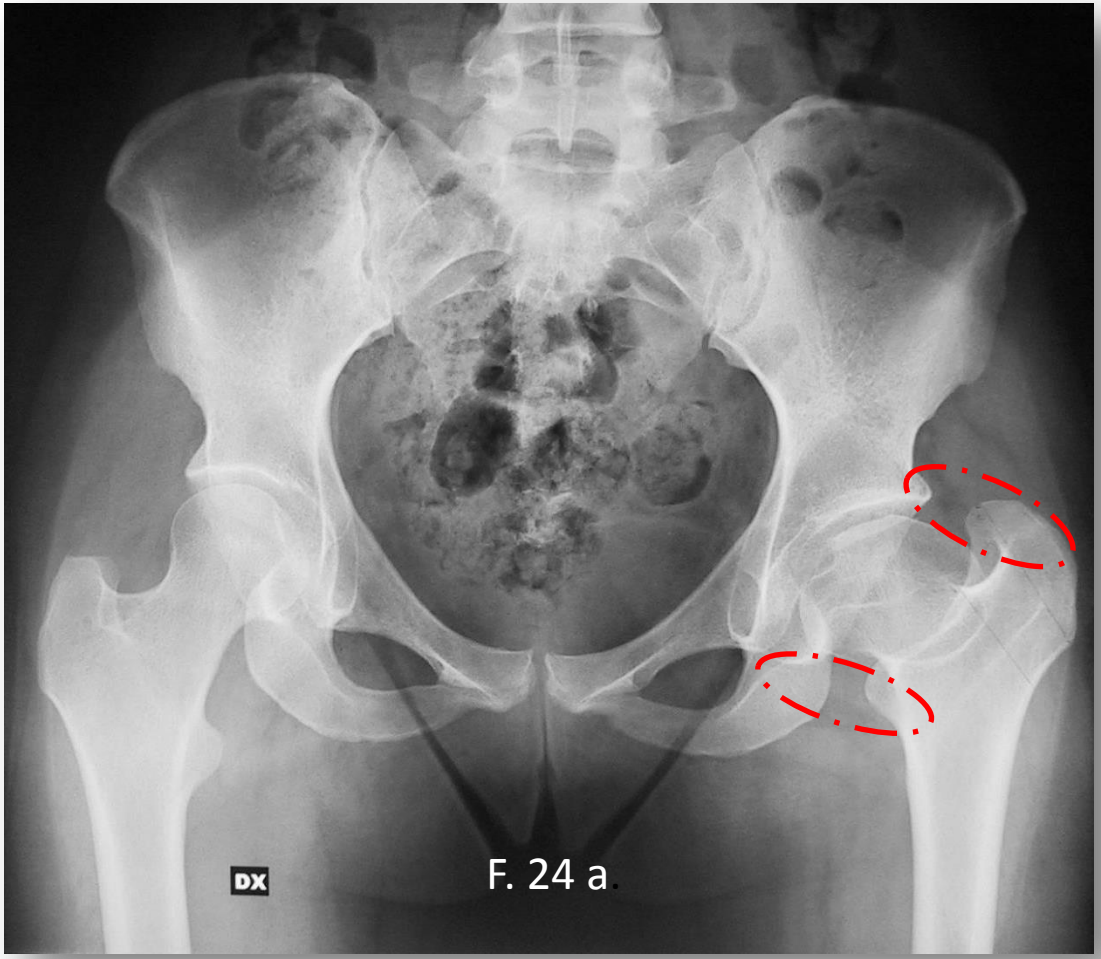

F. 24 a.

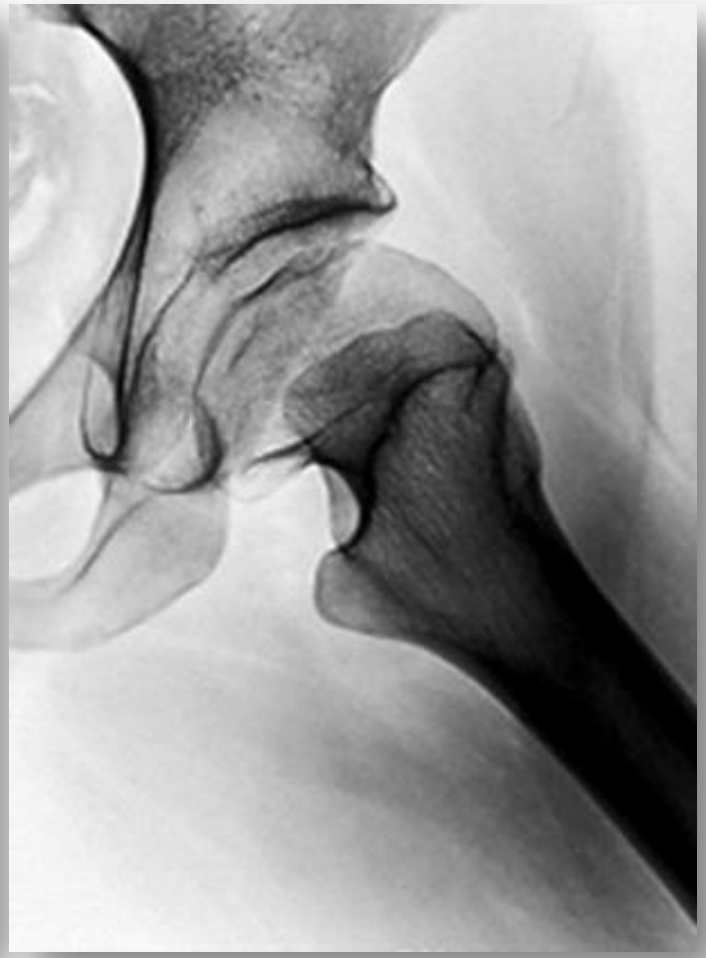

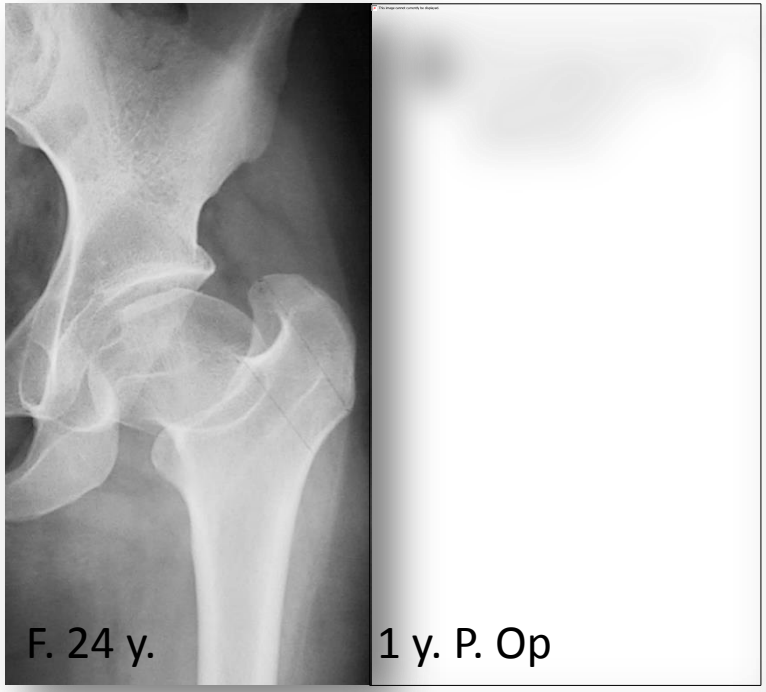
F. 24 y.

1 y. P. Op

In case of:

SCFE



DDH

LCPD

retinacular flap is developed subperiosteally around the entire neck

retinacular flap is developed posteriorly



The femoral head is dislocated and retinacular flap is fully developed around the entire neck



The medial periosteum, including Weitbrecht's ligament and the medial branch of the medial femoral circumflex artery, is dissected

posterior callus is removed and femoral head mobilised

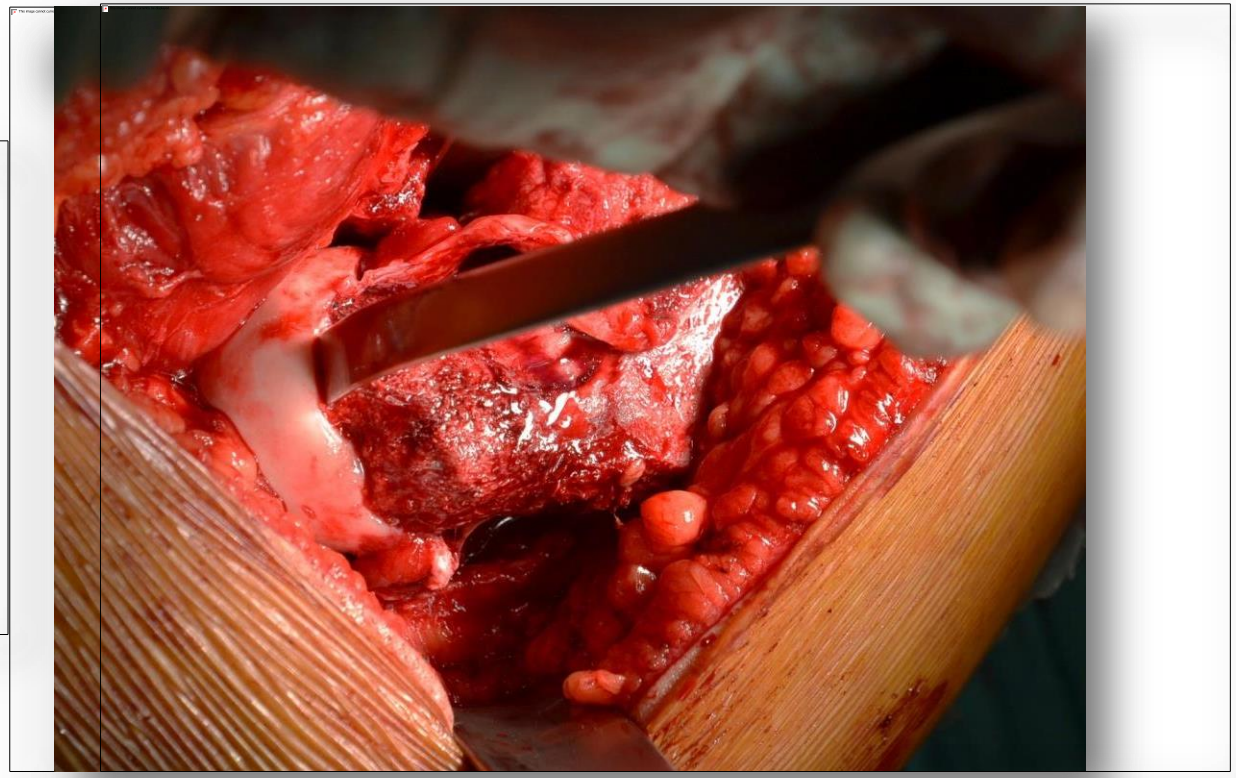

femoral neck is reshaped

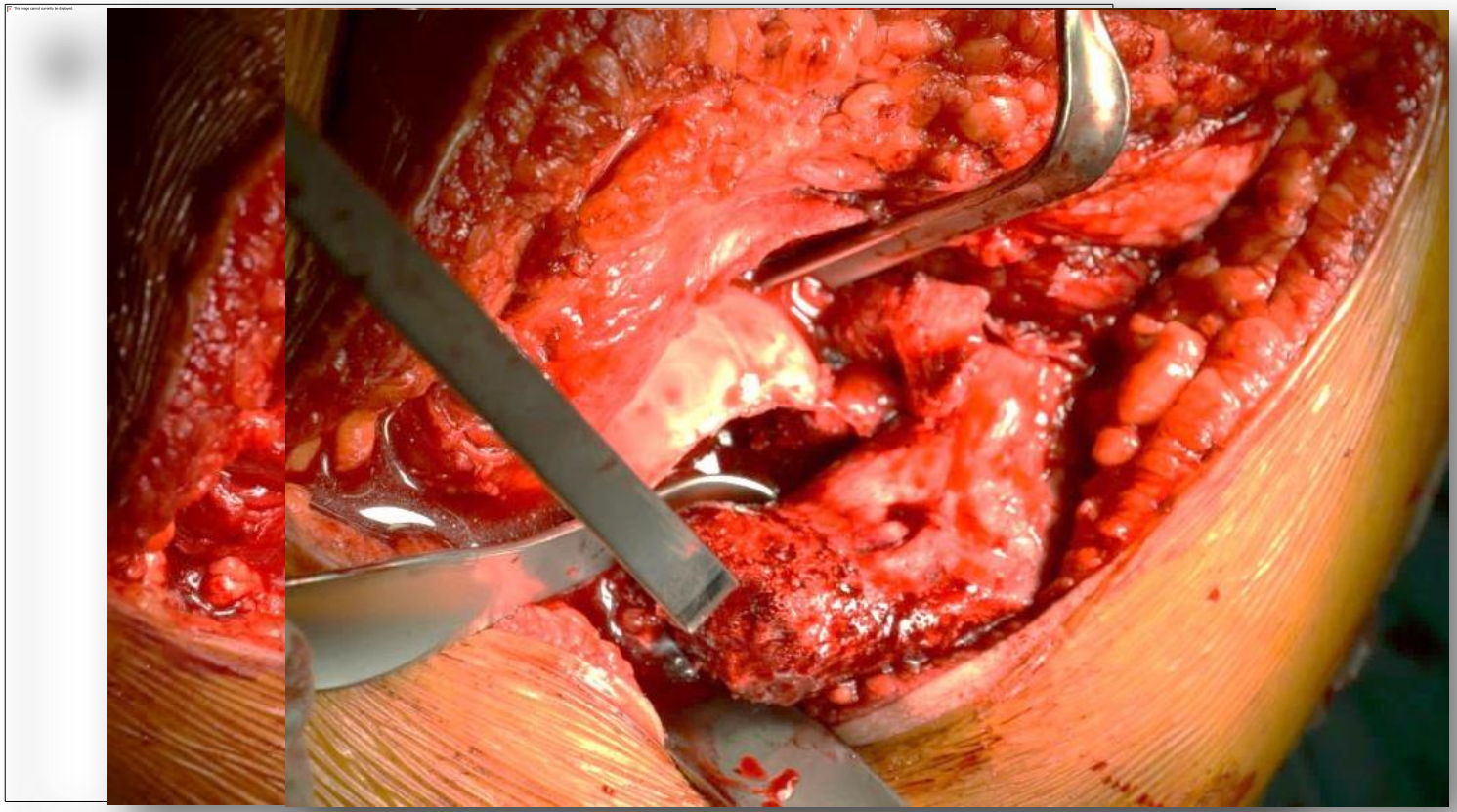

… cleaned and remodeled

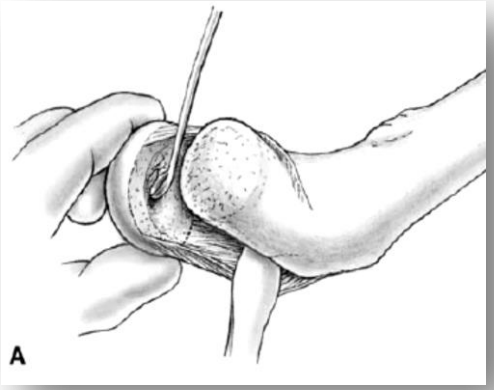

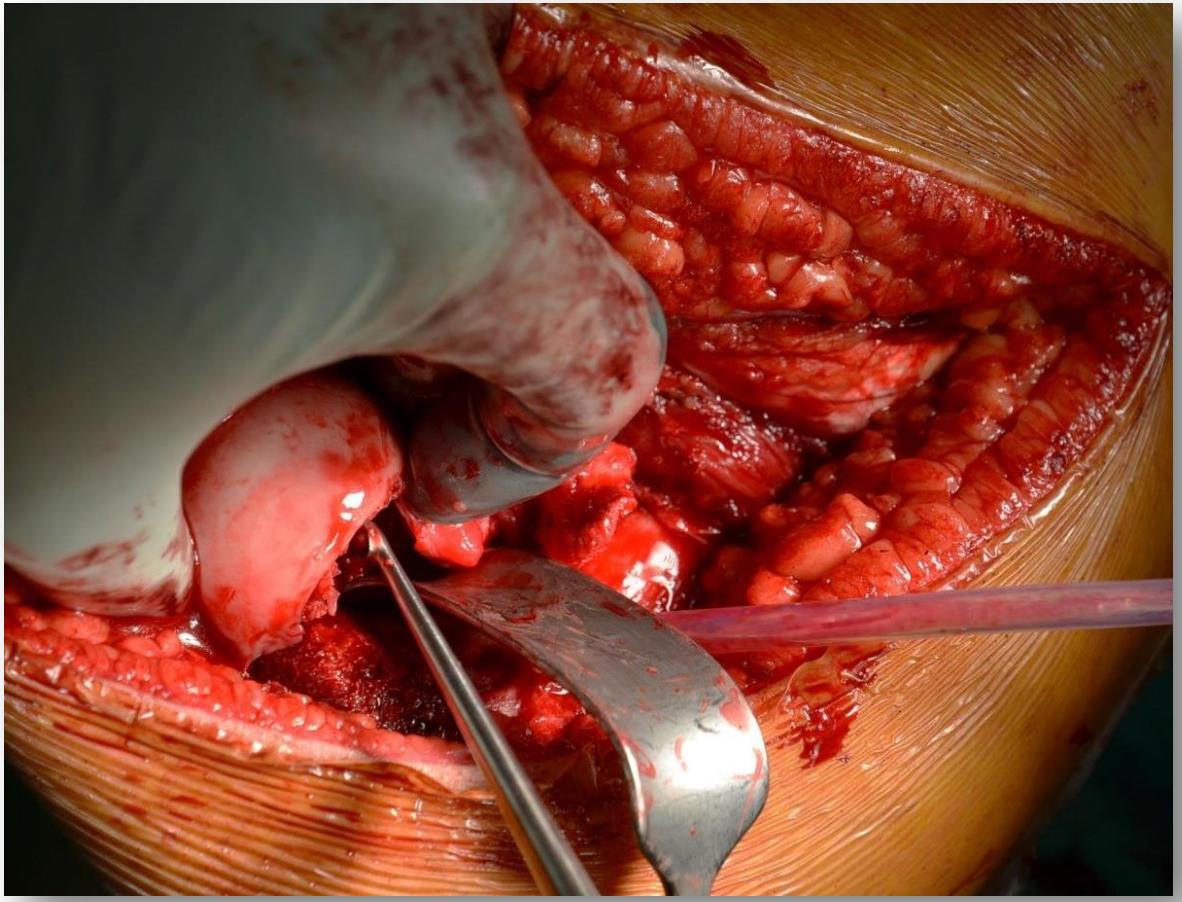

femoral head is reduced and fixed with K wire

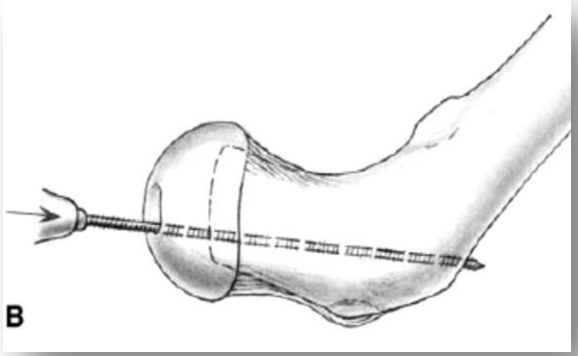

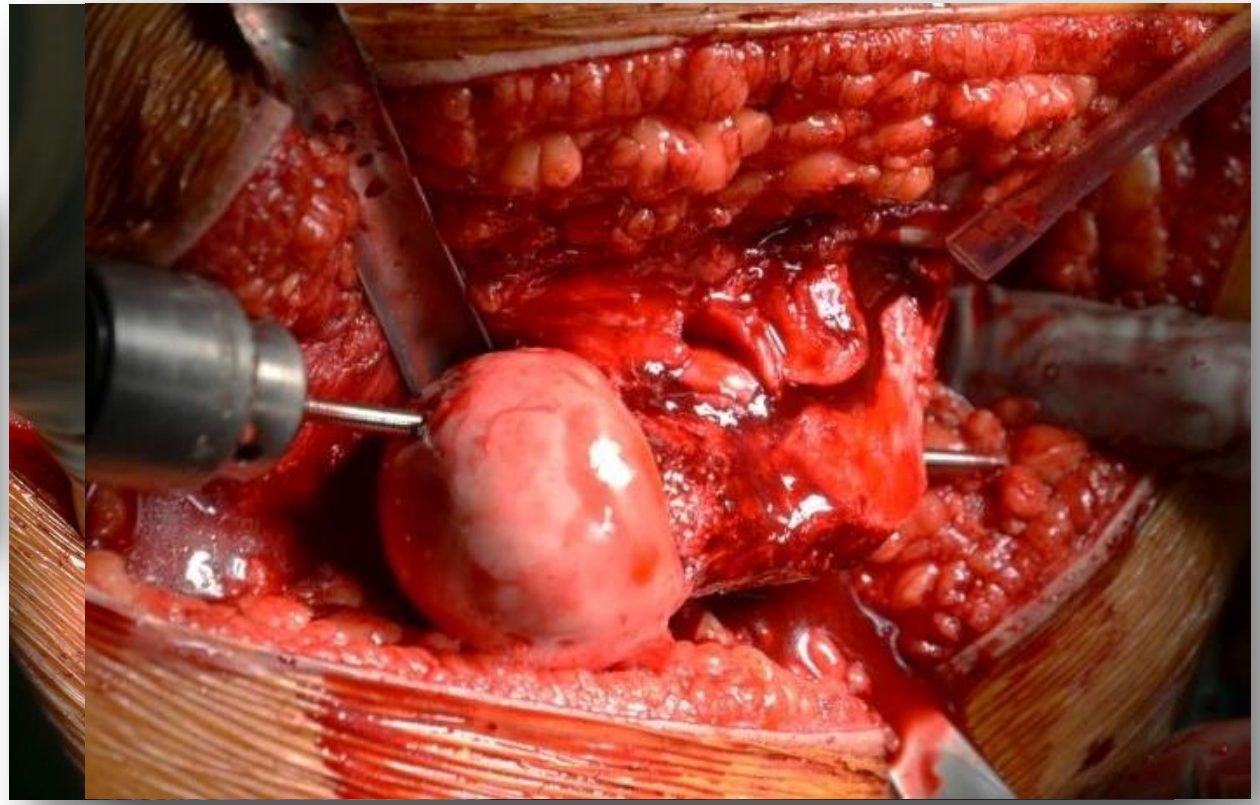



SCFE →



DDH →

LCPD →

Message

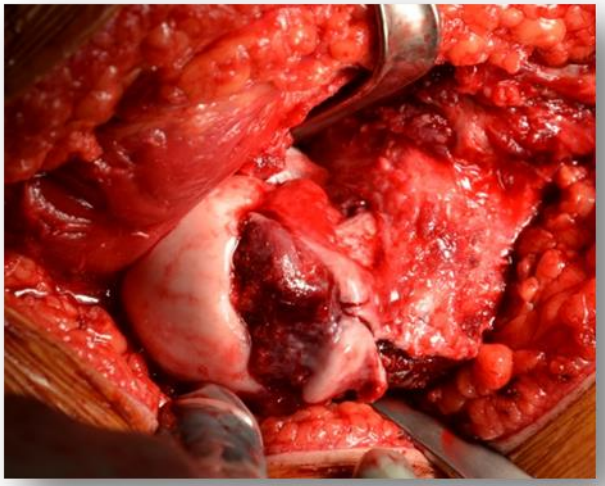

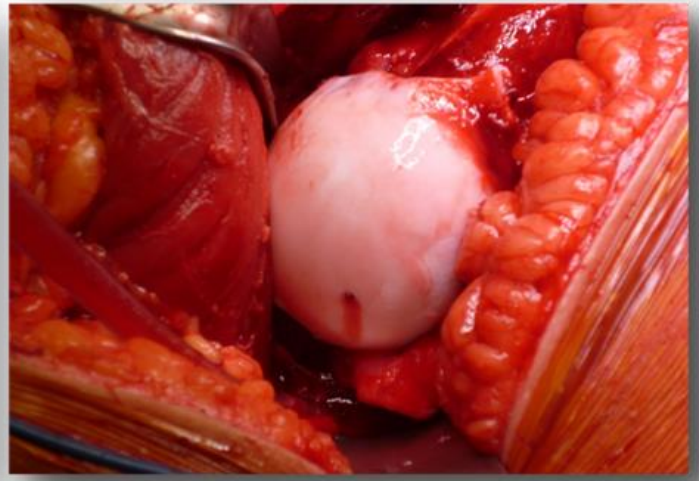

The surgical dislocation of the hip, together with an extended retinacular flap is a safe procedure and can recreate a normal hip anatomy

REGIONE DEL VENETO

ULSS4 VENETO ORIENTALE

Thank you