Differential diagnosis of hip pain

Hubert P. Nötzli, Berne, Switzerland

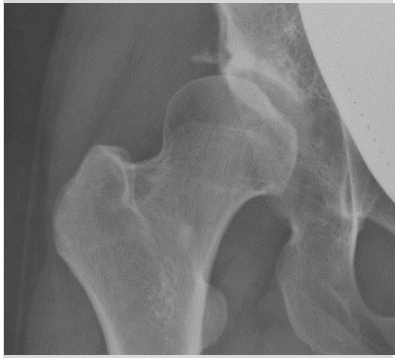

HOSPITAL DA LUZ
LISBOA

Lisbon International Hip Symposium

November, 16th and 17th 2017
Hospital da Luz Lisboa auditorium

“hip pain”

ORTHOPÄDIE SONNENHOF
ortho ▪ spine ▪ sport

DD extra-articular

- Bursitis (trochanter, iliopsoas ...)
- Spinal stenosis
- Ilio-sacral joint and symphysitis pubica
- Stress fractures of the pelvis or the proximal femur
- Tendinitis of muscle insertions
- Hernia
- Morbus Paget
- Tumors
- Infections

“hip pain”

ORTHOPÄDIE SONNENHOF
ortho ▪ spine ▪ sport

DD articular

- Degenerative arthritis
- Inflammatory arthritis
- Femoral head necrosis
- Impingement
- Labral lesion
- Dysplasia
- Stress fractures of the femoral neck
- Tumors, osteolysis
- Septic arthritis
- Multiple osteochondroma
- Old Perthes

ORTHOPÄDIE SONNENHOF
ortho ▪ spine ▪ sport

Patient history

- Trauma
- No significant traumatic event
- Childhood
- Sports

ORTHOPÄDIE SONNENHOF
ortho ▪ spine ▪ sport

Location of pain

Quality of discomfort

Patient history

Symptoms

- Limited hip mobility
- Hypermobility of the hip and/or other joints
- Intermittent groin pain (sharp, stabbing catching)
- Painful hip flexion
- Groin pain during or after sports activities
- Painful adductors with or without traumatic event

Patient history

Triggers

- Activities with rotation in the hip
- Prolonged hip flexion (sitting) uncomfortable/painful
- Rising from seated position (catching, blocking)
- Symptoms with entering/exiting a car
- Intercourse
- Putting on shoes, socks, stockings etc. (deep flexion)
- Walking
- Sport activities

The combination of patient history, symptoms and triggers leads to a diagnosis which has to stand the test of the physical exam.

Clinical exam

Pathologic findings

- Excessive mobility
- Limited hip mobility especially internal rotation
- ± Painful flexion and/or internal rotation

Clinical exam

Pathologic findings

- Excessive mobility
- Limited hip mobility especially internal rotation
- ± Painful flexion and/or internal rotation
- ± Trendelenburg gait/sign

Clinical exam

Pathologic findings

- Excessive mobility
- Limited hip mobility especially internal rotation
- ± Painful flexion and/or internal rotation
- ± Trendelenburg gait/sign
- ± Abductor weakness

Abductor weakness

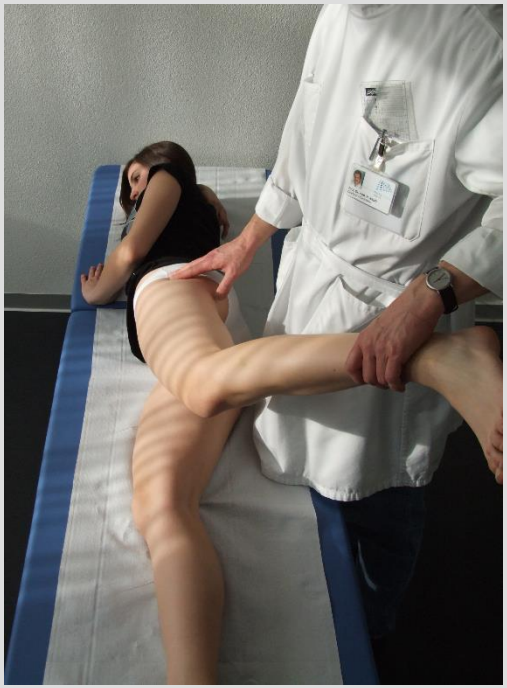

Clinical exam

Pathologic findings

- Excessive mobility
- Limited hip mobility especially internal rotation
- ± Painful flexion and/or internal rotation
- ± Trendelenburg gait/sign
- ± Abductor weakness
- Impingement sign + to +++

Impingement sign

Dynamic internal rotation/adduction maneuver of the flexed hip

Impingement sign

Various flexion positions of the hip help to determine the size of the lesion

ORTHOPÄDIE SONNENHOF
ortho ▪ spine ▪ sport

C-sign

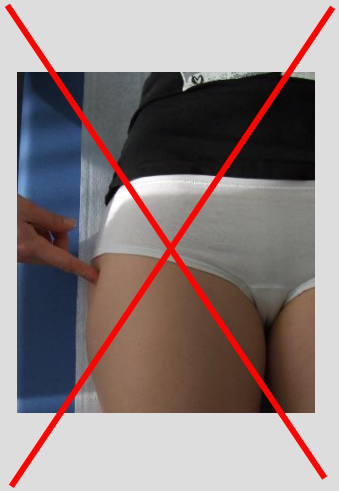

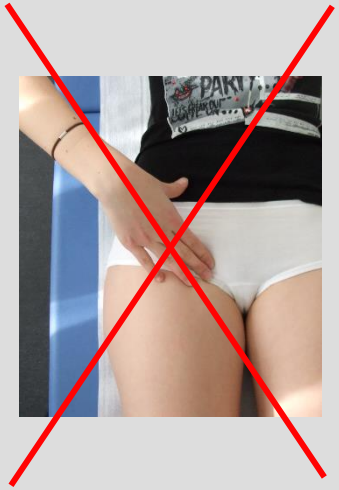

„C-sign“ characteristic for an intraarticular problem

Exclusion of a hernia

Clinical exam

Pathologic findings

- Excessive mobility
- Limited hip mobility especially internal rotation
- ± Painful flexion and/or internal rotation
- ± Trendelenburg gait/sign
- ± Abductor weakness
- Impingement sign + to +++
- Apprehension sign –

Apprehension sign

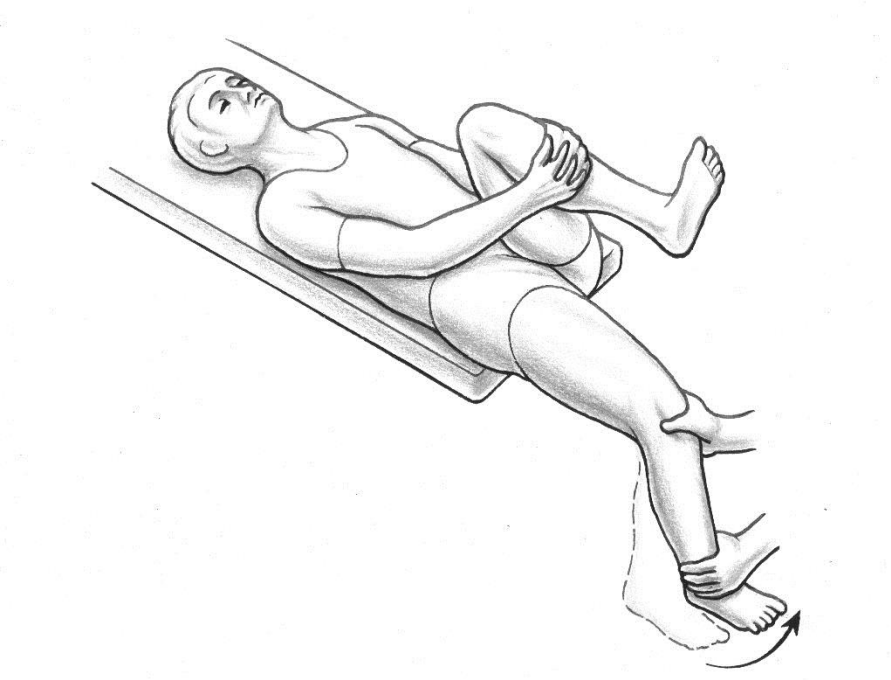

Pelvic tilt uncovers the femoral head loading the labrum and provoking pain in an affected labrum

Tractus loading test

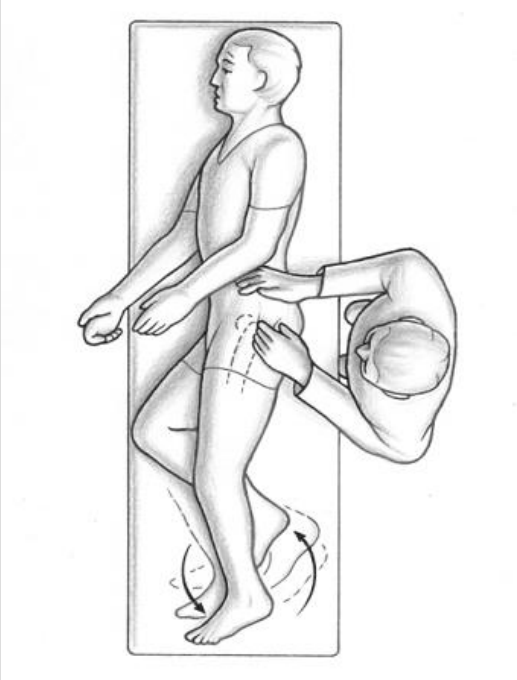

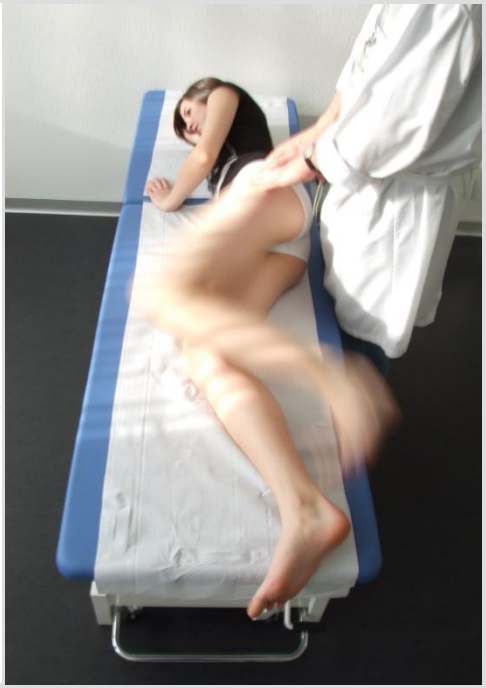

Bike movement in lateral decubitus position

Coxa saltans, snapping of the iliotibial band
Bursitis trochanterica

Typically associated with abductor weakness

Iliopsoas snapping

„Clunk“ phenomenon when the straight abducted and externally rotated leg from the flexed position moves toward extension and internal rotation

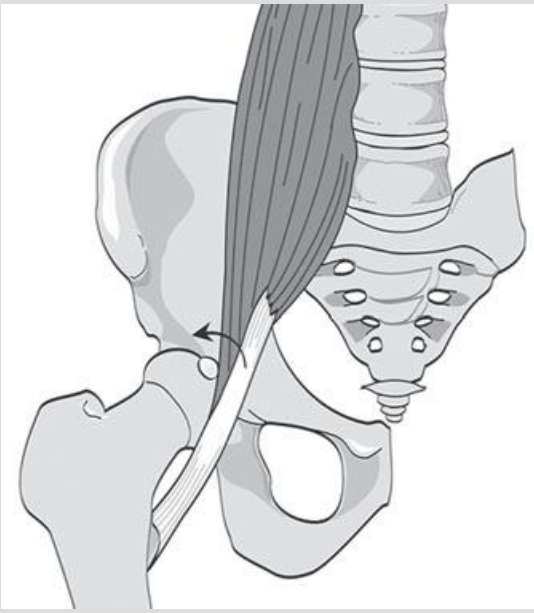

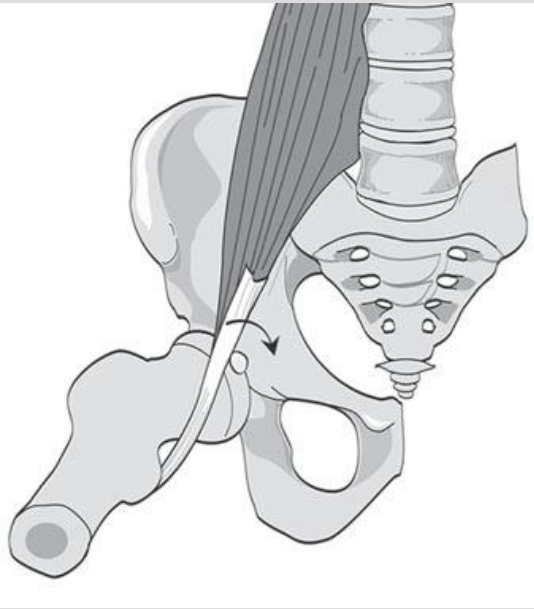

Mélanie Deslandes et al. AJR:190, March 2008

Snapping as the psoas tendon crosses anterior femoral head & capsule or pectineal eminence

ORTHOPÄDIE SONNENHOF
ortho ▪ spine ▪ sport

Hilton‘s law by John Hilton (1804-1878)

„The same trunks of nerves whose branches supply the groups of muscles moving a joint furnish also a distribution of nerves in the skin over the insertion of the same muscles, and the interior of the joint receives its nerves from the same source.“

ORTHOPÄDIE SONNENHOF
ortho ▪ spine ▪ sport

Triggerpoints of the iliopsoas muscle

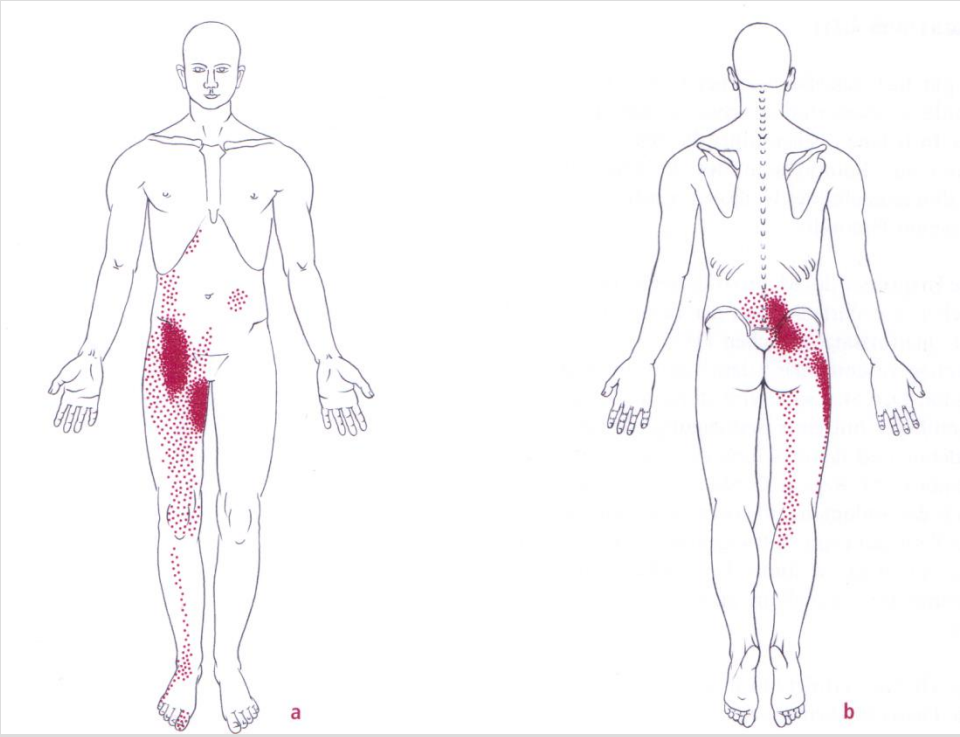

Beat Dejung; Triggerpunkbehandlung; Hans Huber Verlag 2006

Muscular dysbalance

Abductor weakness

Adductor hypertonus

ORTHOPÄDIE SONNENHOF
ortho ▪ spine ▪ sport

Short muscles, tendinitis

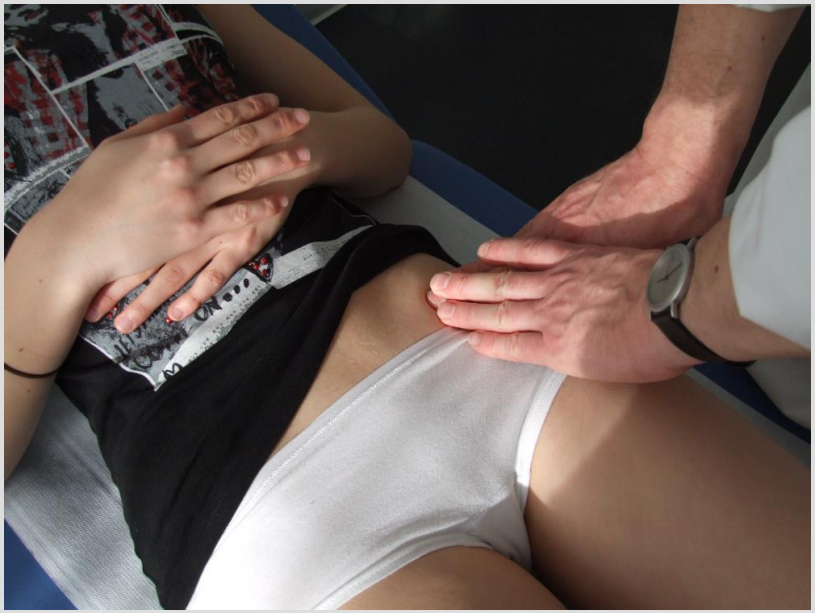

ORTHOPÄDIE SONNENHOF
ortho ▪ spine ▪ sport

What is important?

Groin pain is not equal to an intraarticular problem

Try to distinguish between intraarticular and extraarticular pain

Pain which is provoked during the exam must be typical for the patient

If MRI and clinical exam don‘t correspond go for the clinic

ORTHOPÄDIE
SONNENHOF
ortho ▪ spine ▪ sport

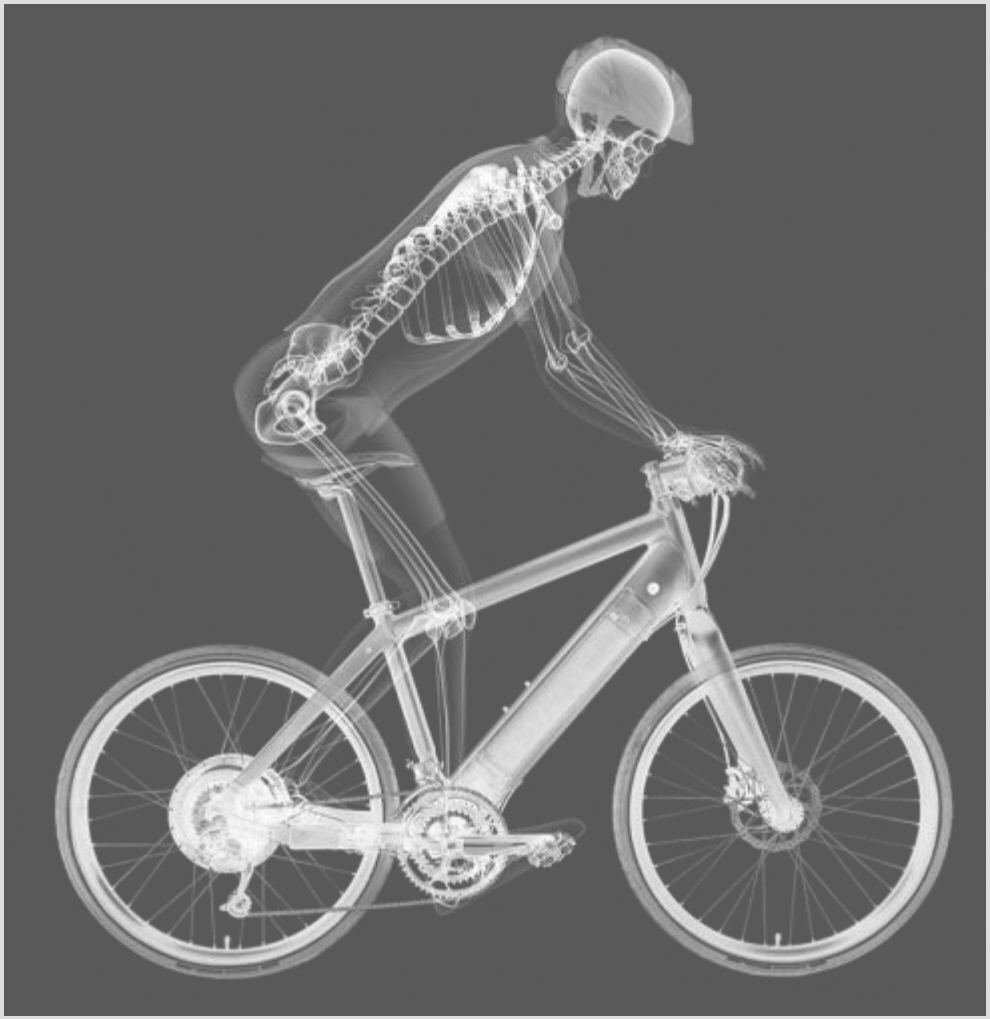

ORTHOPÄDIE
SONNENHOF
ortho ▪ spine ▪ sport



FIGVRA QVARTA
a
a
a
A
B
b
D
C
a
FIGVRA QVINTA

X-Rays in two planes

pelvis a.-p.

cross table view

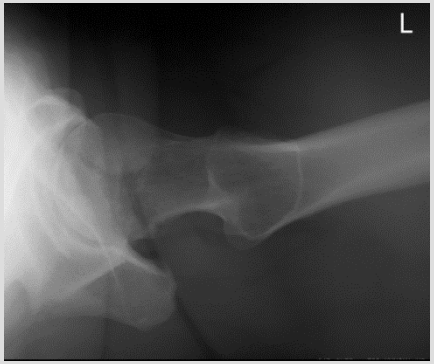

Basic Patient Position

The patient lies supine on the table with the midsaggital line in the center of the table. The legs are internally rotated that the patellae point to the ceiling by separating the heels 10cm and bring the toes together in order to bring the femoral necks parallel to the film to reduce foreshortening.

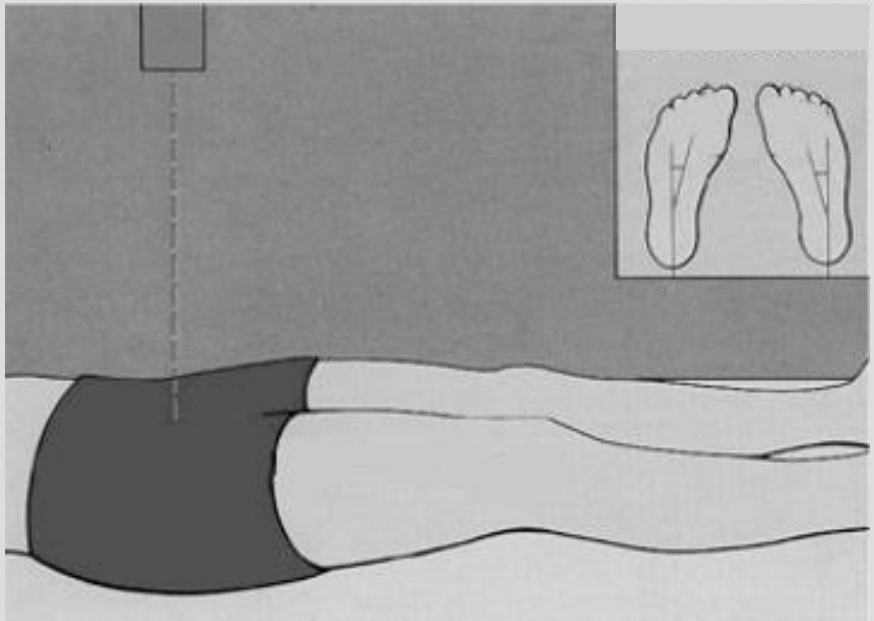

X-Rays in two planes

pelvis a.-p.

cross table view

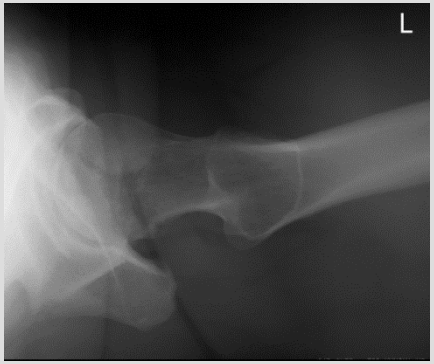

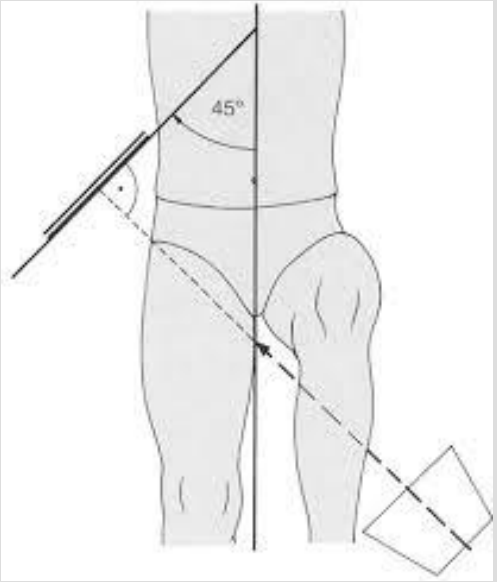
45°

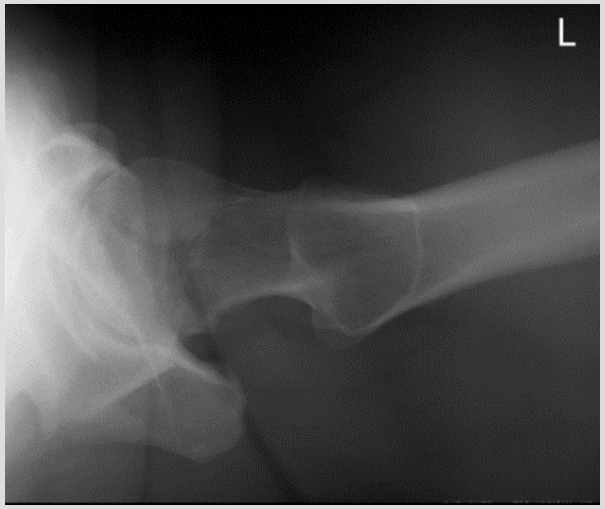
L

Faux profil view (Incidence of Lequesne)

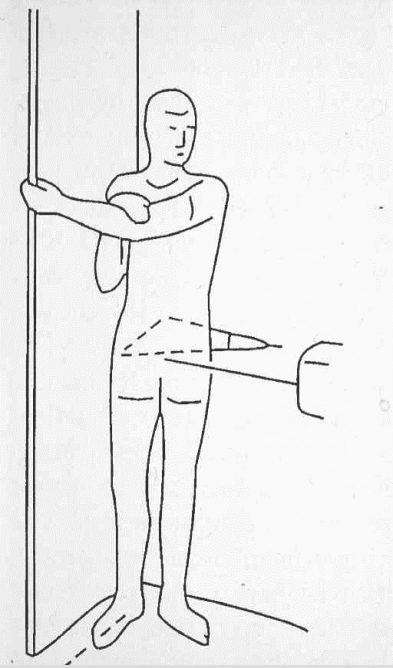

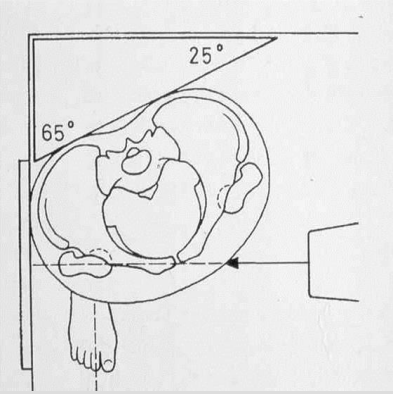

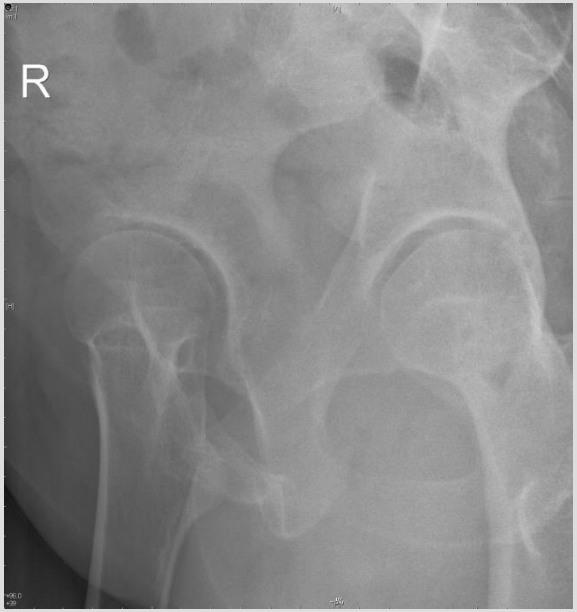

Dunn/Rippstein/Müller

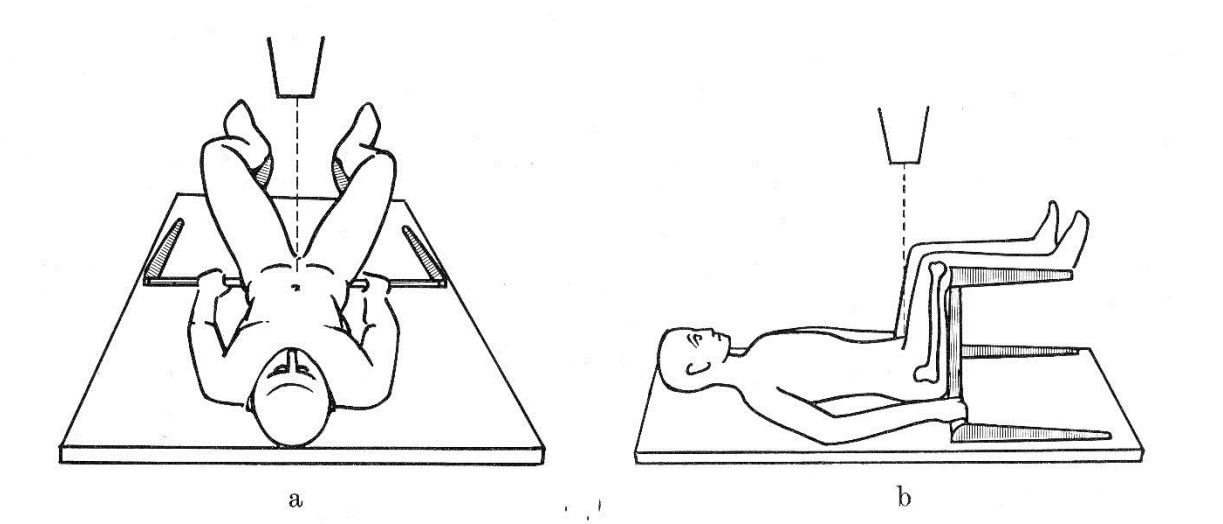



M.E.Müller: Die hüftnahen Femurosteotomien, 1971

Patient f, age 14

ORTHOPÄDIE SONNENHOF
ortho ▪ spine ▪ sport

Torsion

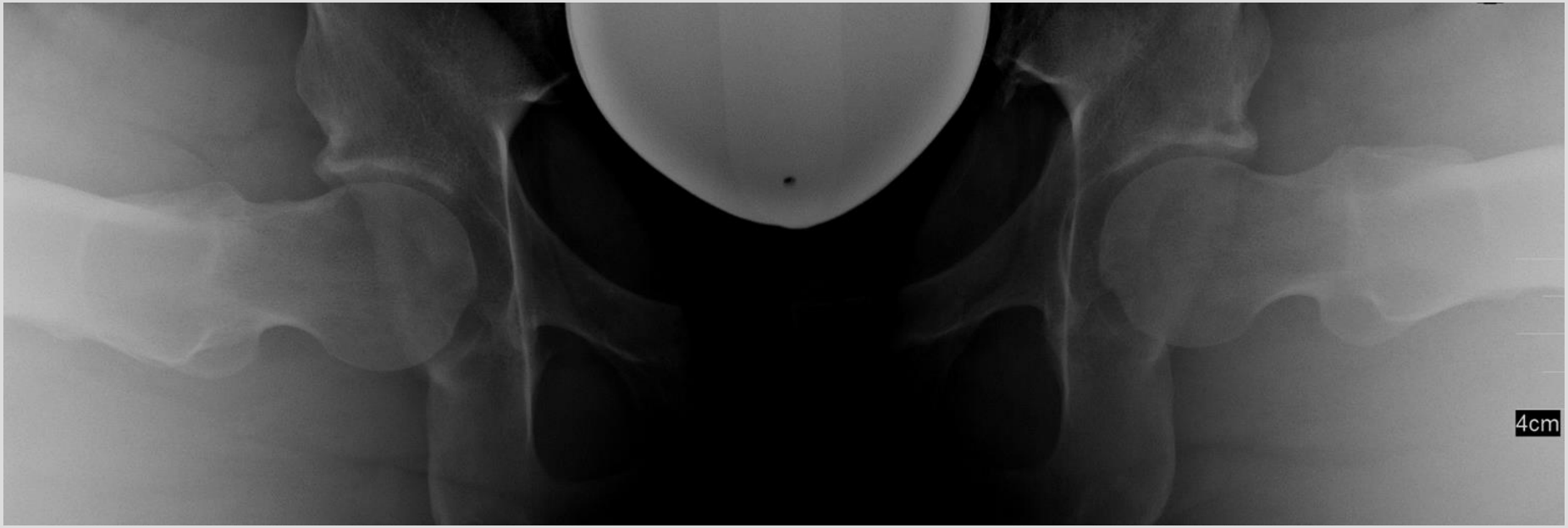

ORTHOPÄDIE
SONNENHOF
ortho ▪ spine ▪ sport

ORTHOPÄDIE SONNENHOF
ortho ▪ spine ▪ sport

Acetabular-Index

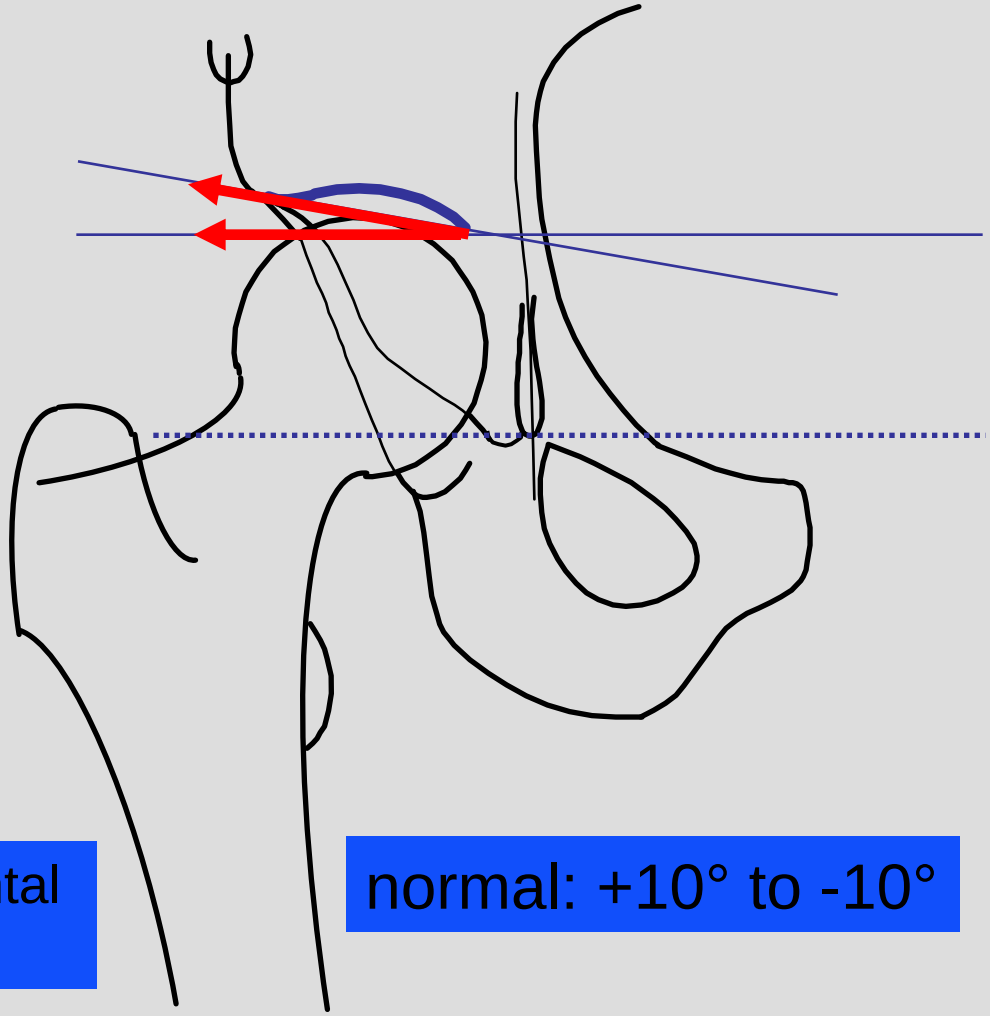

A normal hip has a horizontal weight bearing area

normal: +10° to -10°

ORTHOPÄDIE SONNENHOF
ortho ▪ spine ▪ sport

LCE - angle (Wiberg)



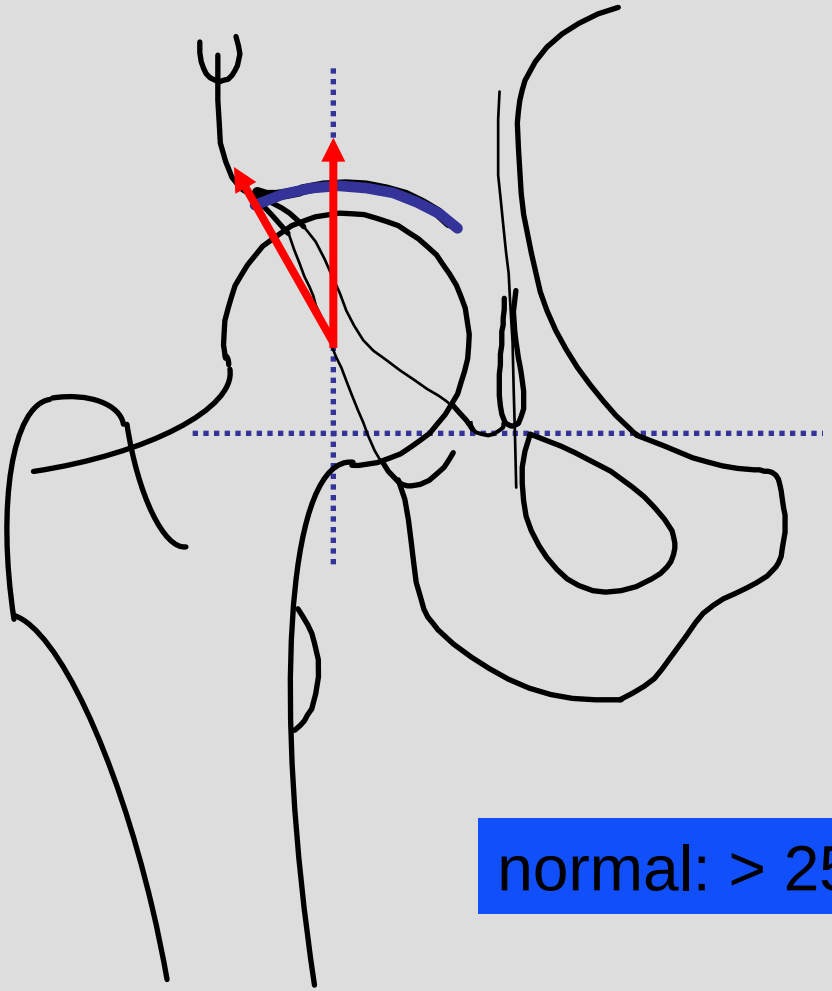

normal: > 25°

ORTHOPÄDIE SONNENHOF
ortho ▪ spine ▪ sport

ACE-angle (Lequesne)

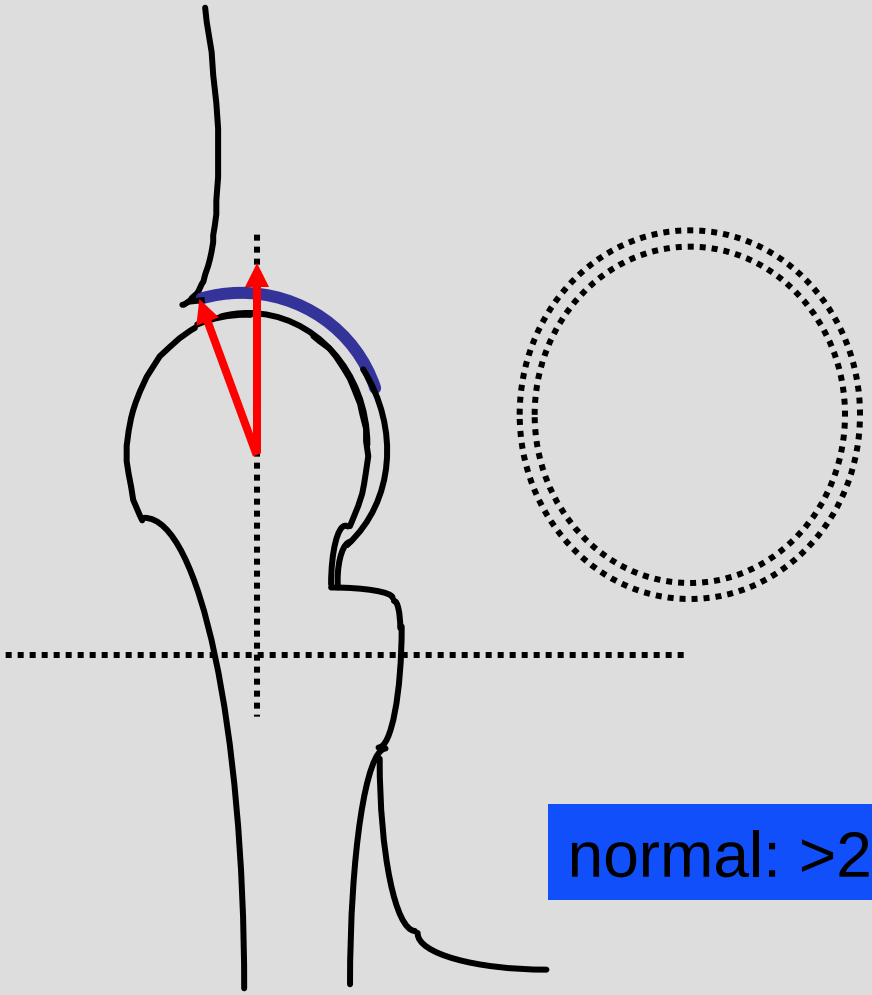

normal: >25°

ORTHOPÄDIE
SONNENHOF
ortho ▪ spine ▪ sport

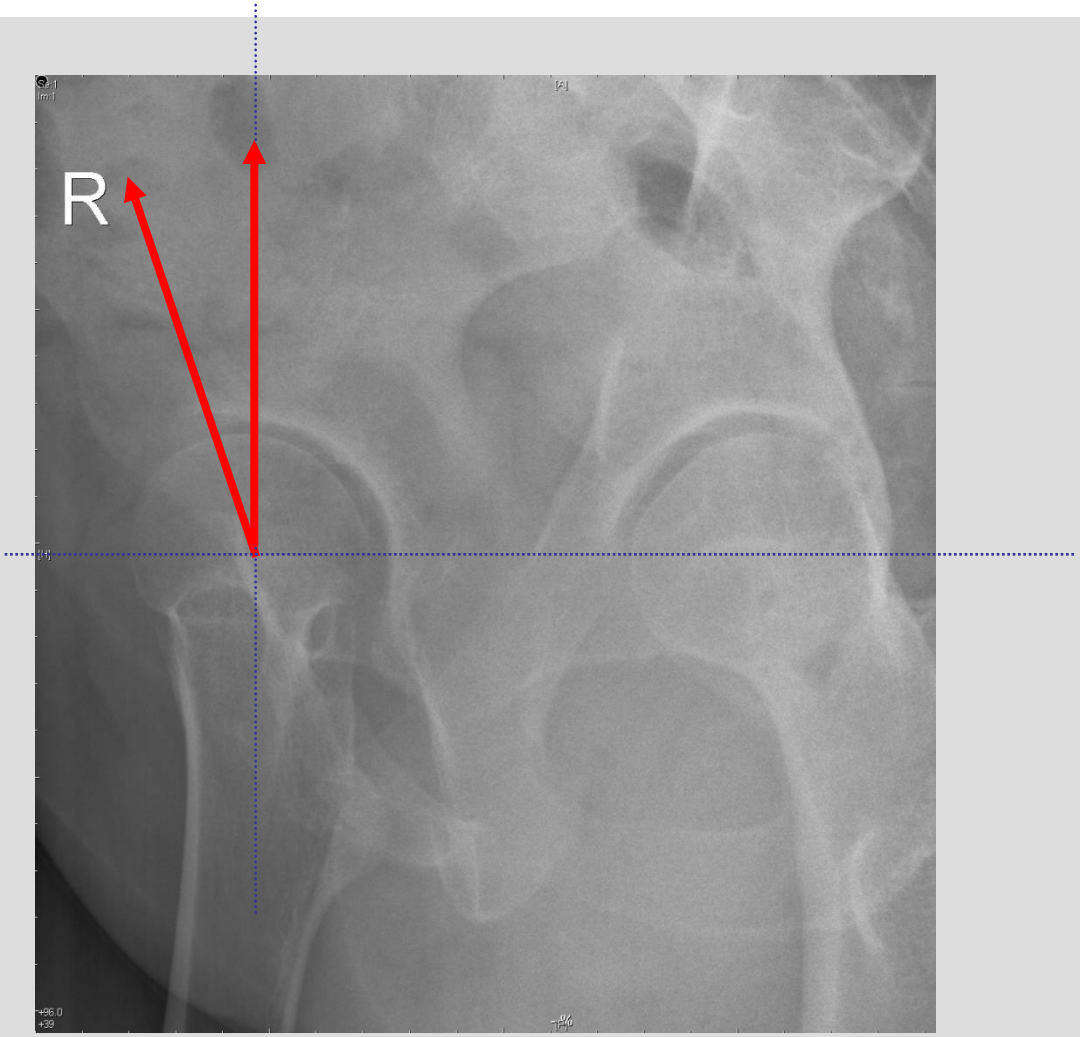

ORTHOPÄDIE SONNENHOF
ortho ▪ spine ▪ sport

Teardrop-figure
(Koehler)

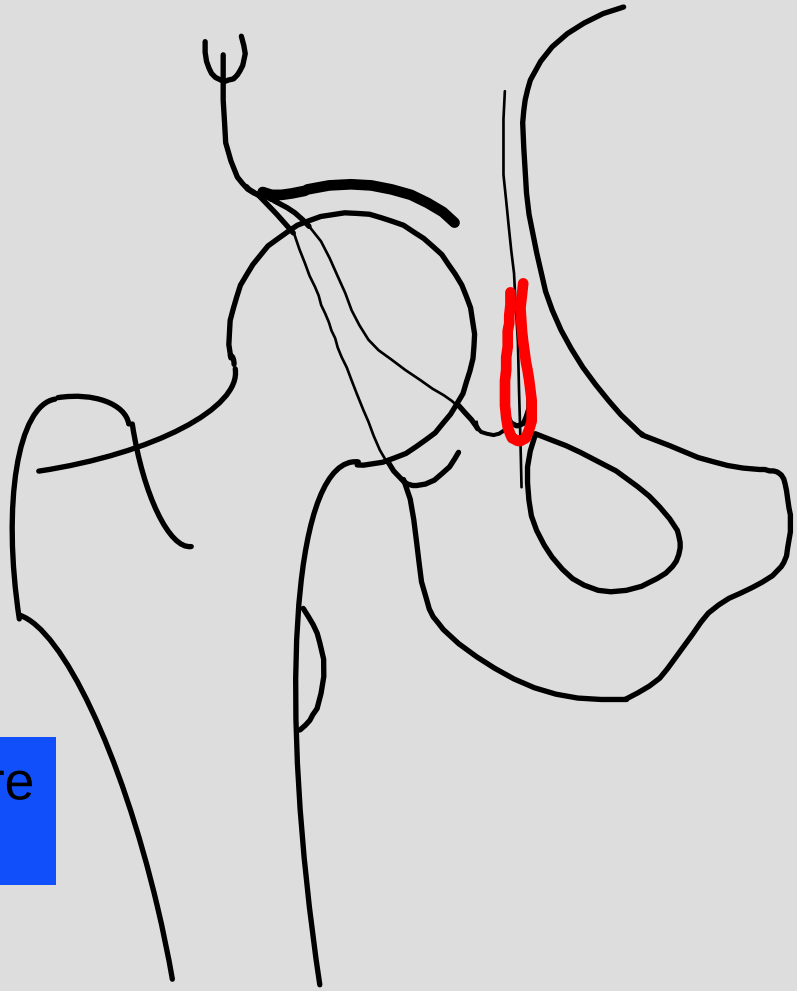

A normal teardrop figure is slim

ORTHOPÄDIE SONNENHOF
ortho ▪ spine ▪ sport

Teardrop-figure
(Koehler)

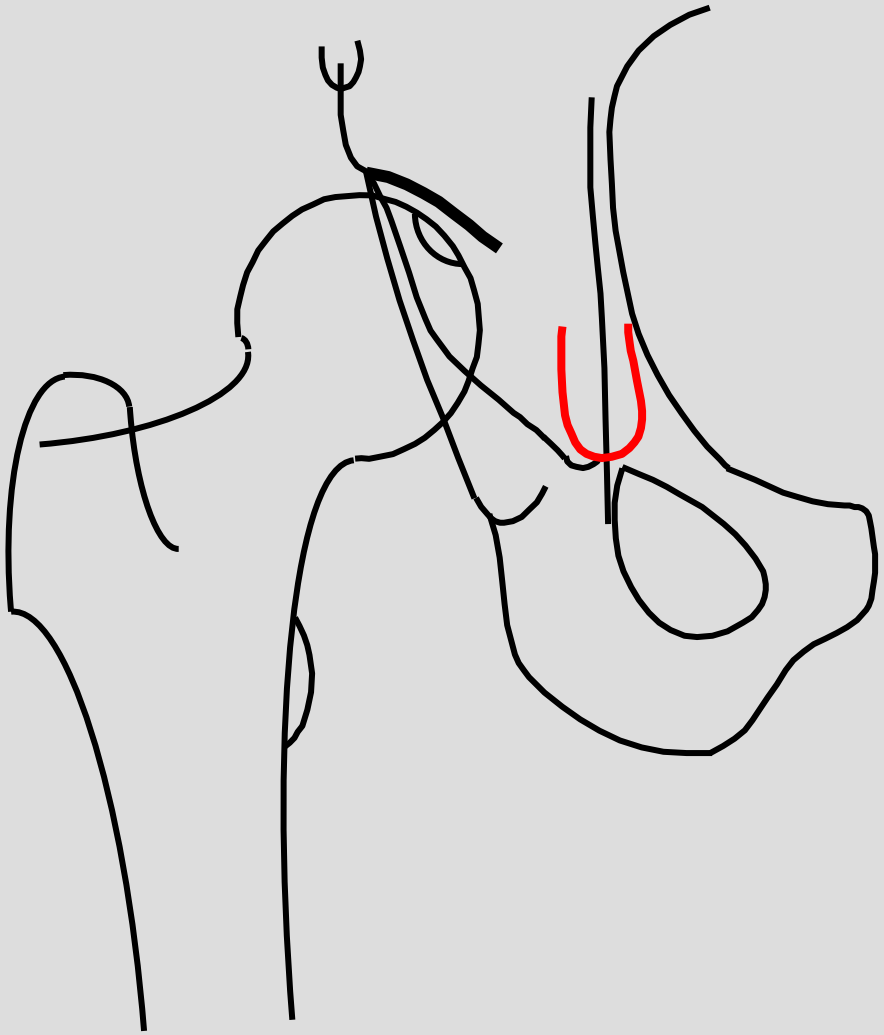

ORTHOPÄDIE SONNENHOF
ortho ▪ spine ▪ sport

Teardrop figure (Koehler)

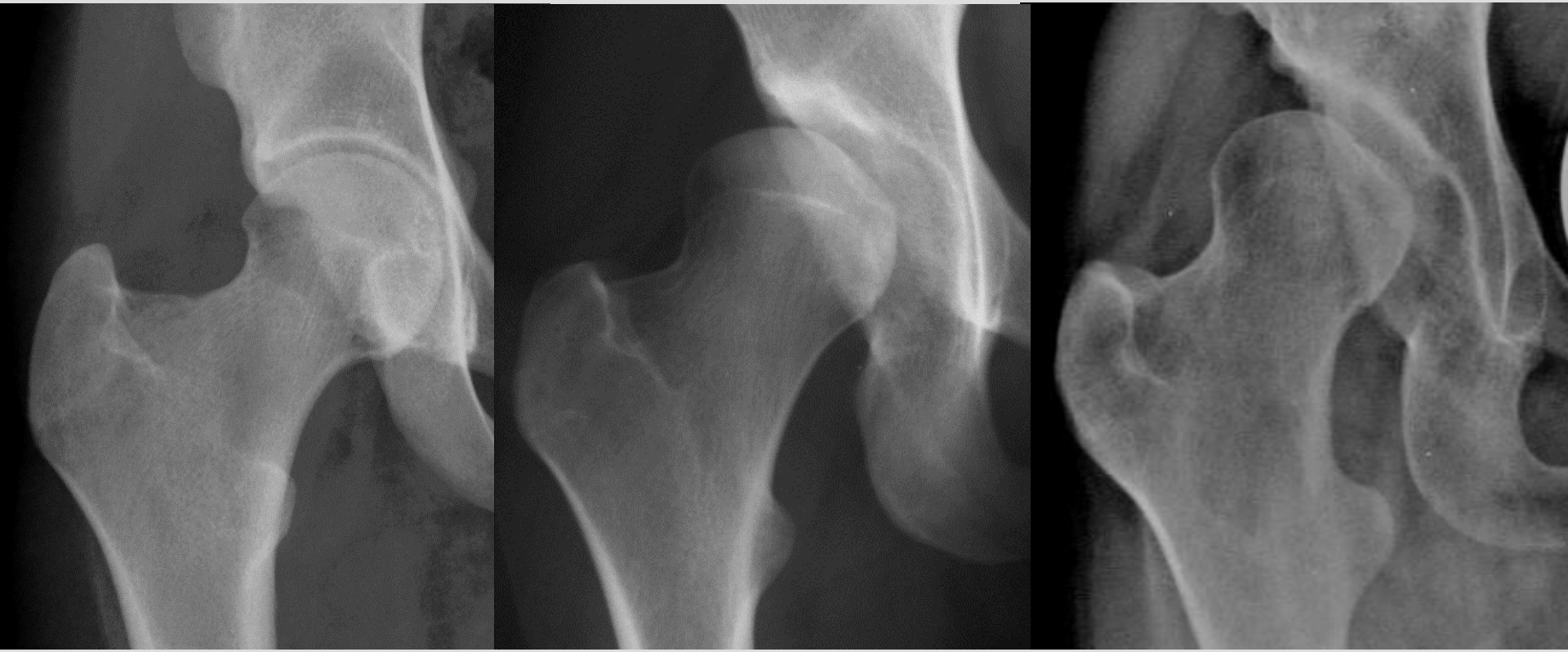

ORTHOPÄDIE SONNENHOF
ortho ▪ spine ▪ sport

Ilio-ischial line

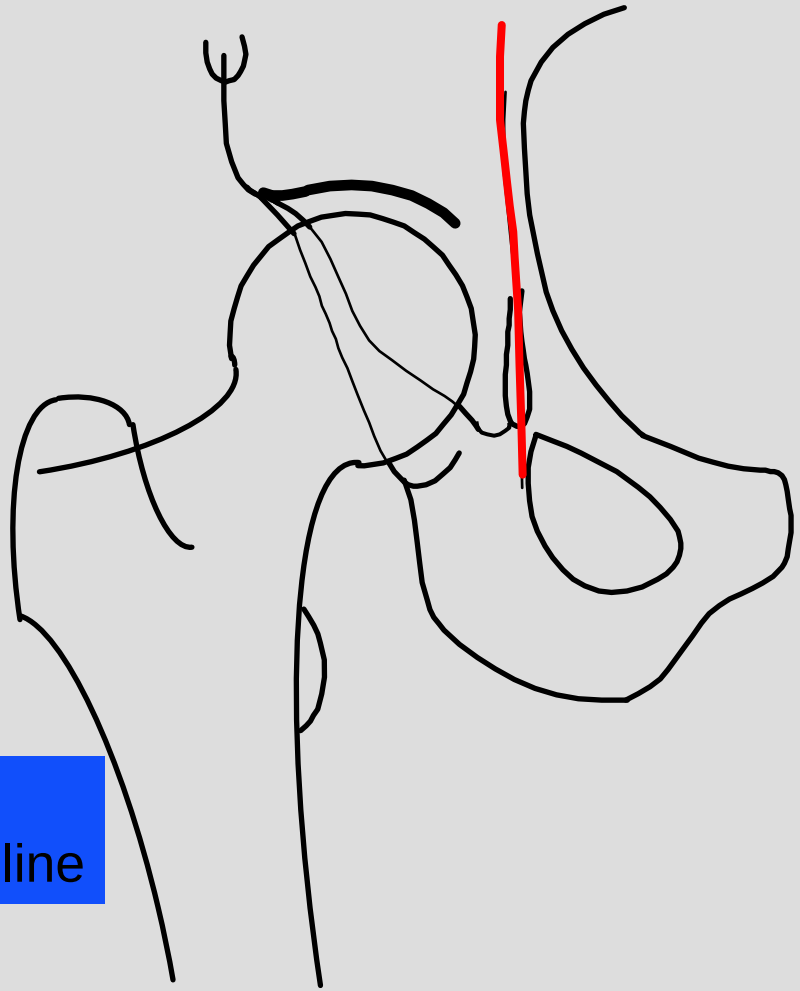

Neither the acetabulum nor the femoral head cuts the ilio-ischial line

ORTHOPÄDIE SONNENHOF
ortho ▪ spine ▪ sport

Ilio-ischial line

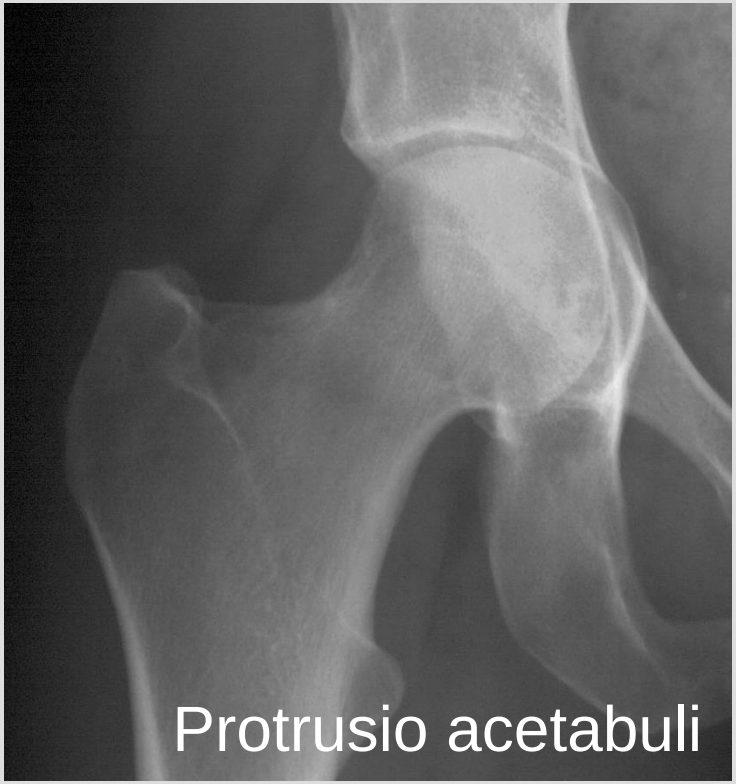

ORTHOPÄDIE SONNENHOF
ortho ▪ spine ▪ sport

Posterior and anterior wall of the acetabulum

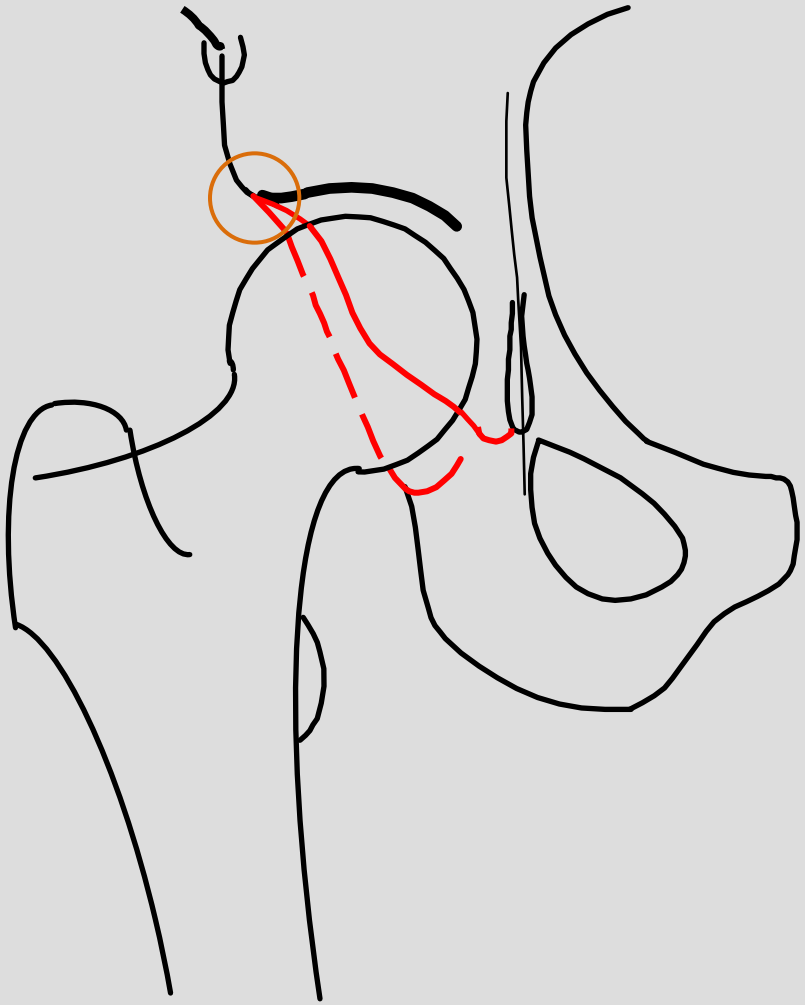

Posterior and anterior wall of the acetabulum end at the same proximal point

ORTHOPÄDIE SONNENHOF
ortho ▪ spine ▪ sport

Retroversion

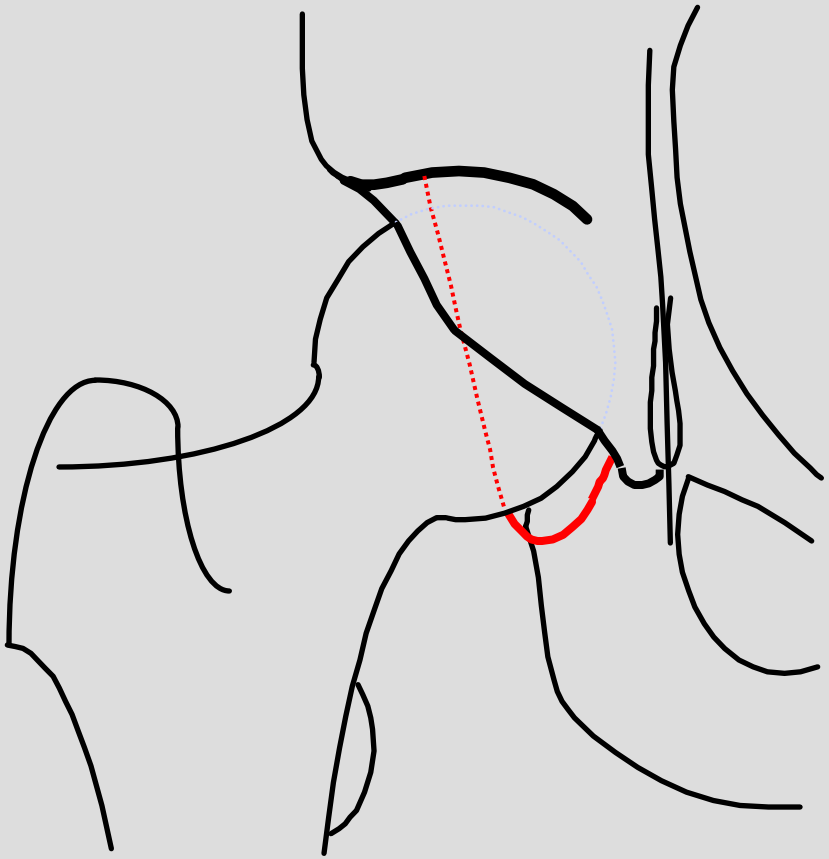

Anteversion

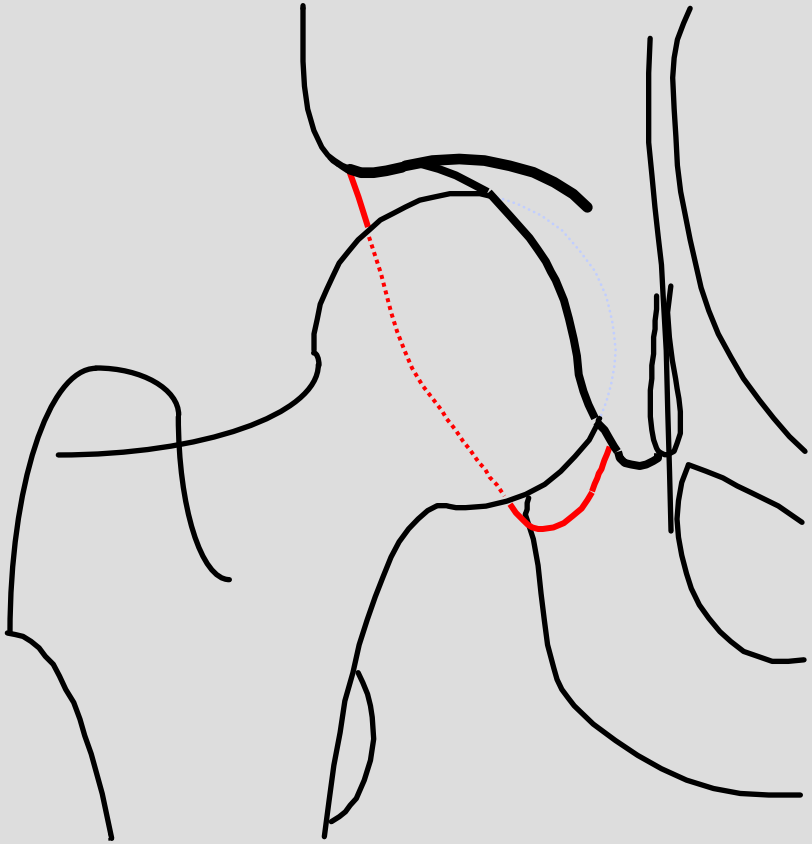

ORTHOPÄDIE
SONNENHOF
ortho ▪ spine ▪ sport

ORTHOPÄDIE
SONNENHOF
ortho ▪ spine ▪ sport

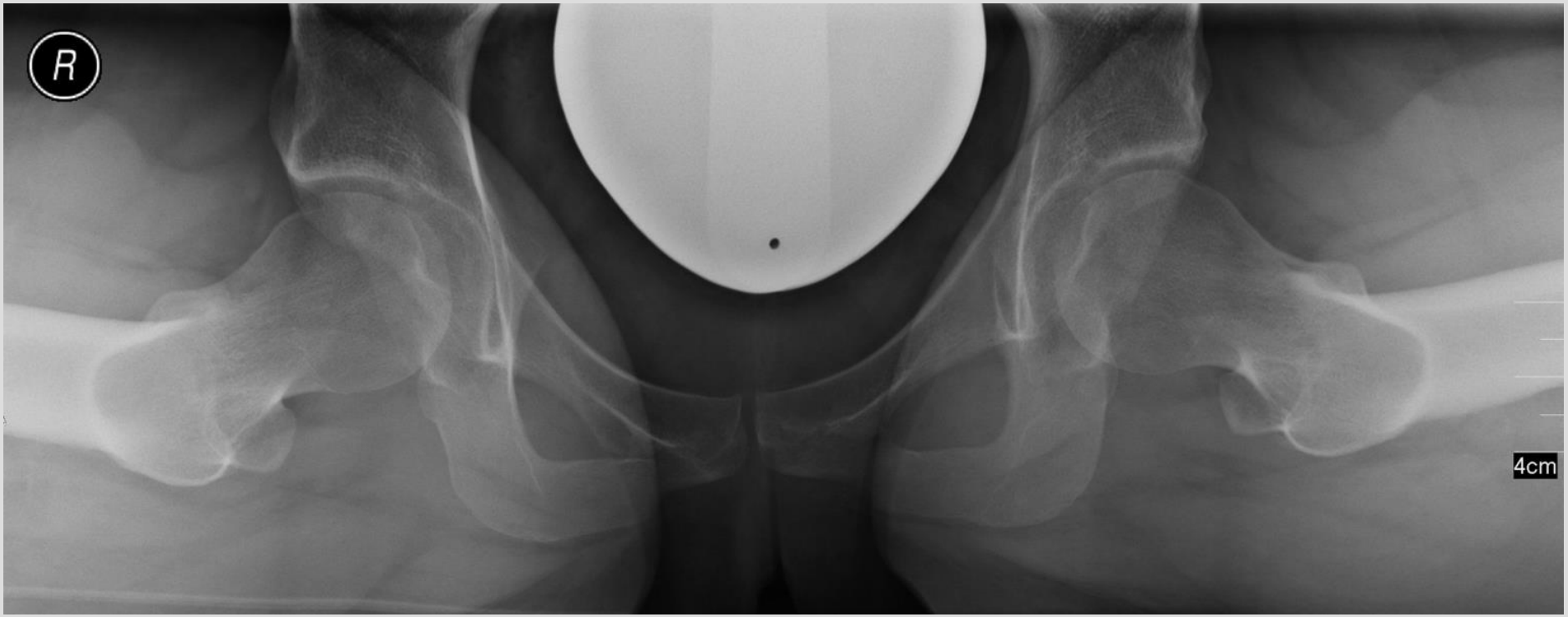

ORTHOPÄDIE
SONNENHOF
ortho ▪ spine ▪ sport

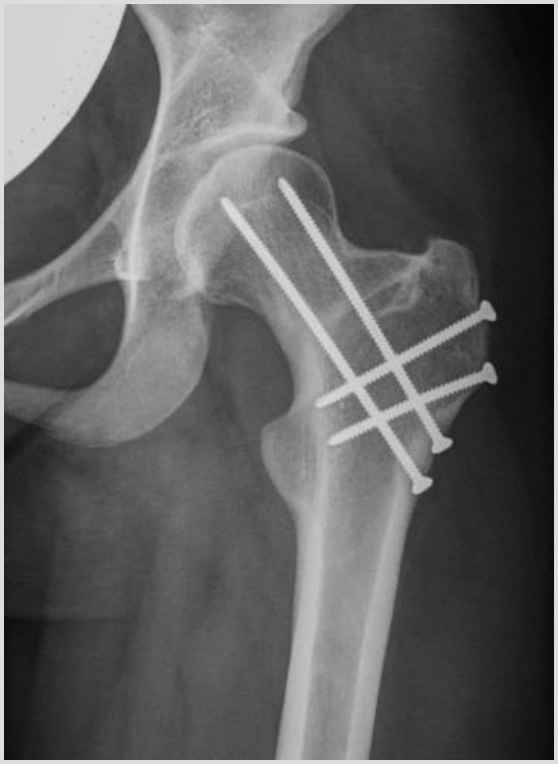

ORTHOPÄDIE SONNENHOF
ortho ▪ spine ▪ sport

- Arthro-MRI with coil

ORTHOPÄDIE
SONNENHOF
ortho ▪ spine ▪ sport

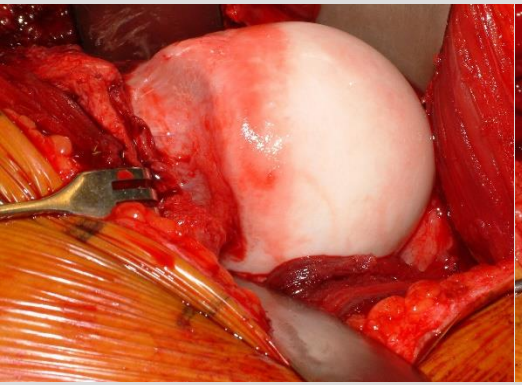
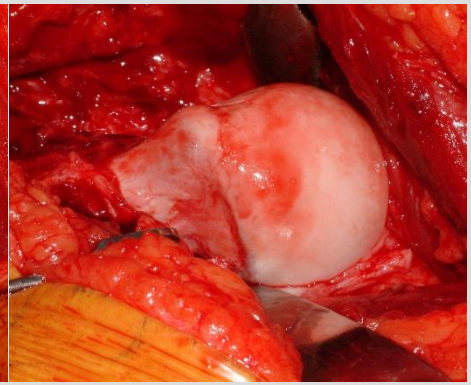

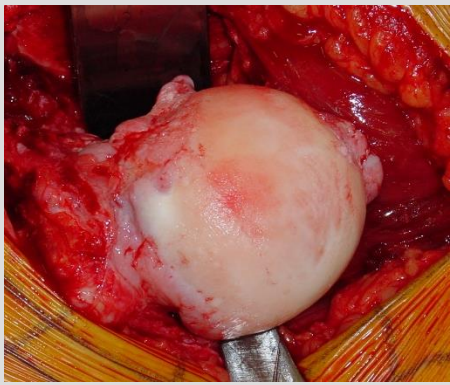

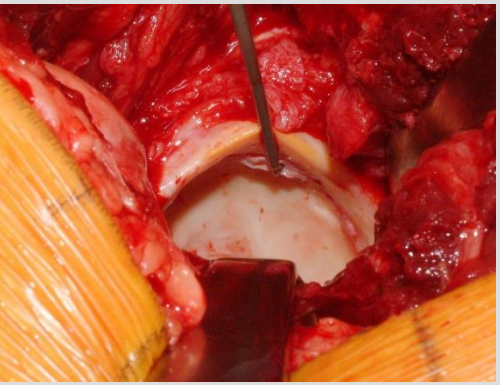
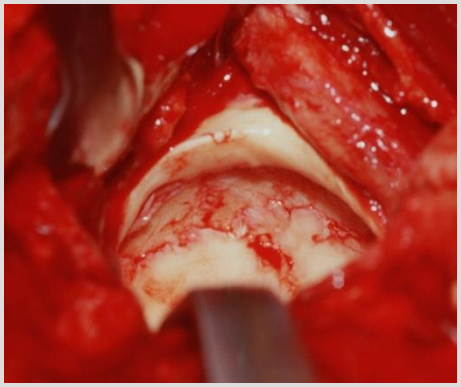
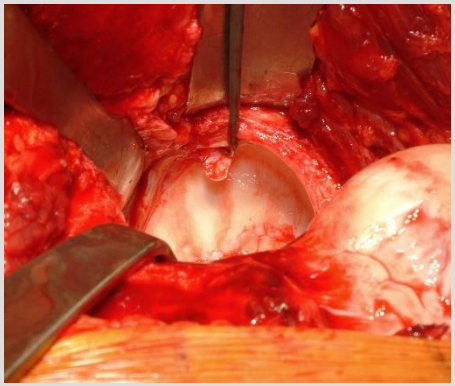
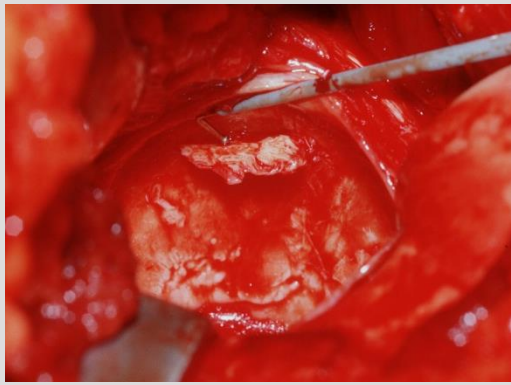

ORTHOPÄDIE SONNENHOF
ortho ▪ spine ▪ sport

Take home message

- X-Ray technique should be standardized
- Findings have to be interpreted with care
- Keep in mind that the hip has two parts ->
  A pathologic finding on one side may be compensated or aggravated by the other joint part

ORTHOPÄDIE SONNENHOF
ortho ▪ spine ▪ sport

Thank you!